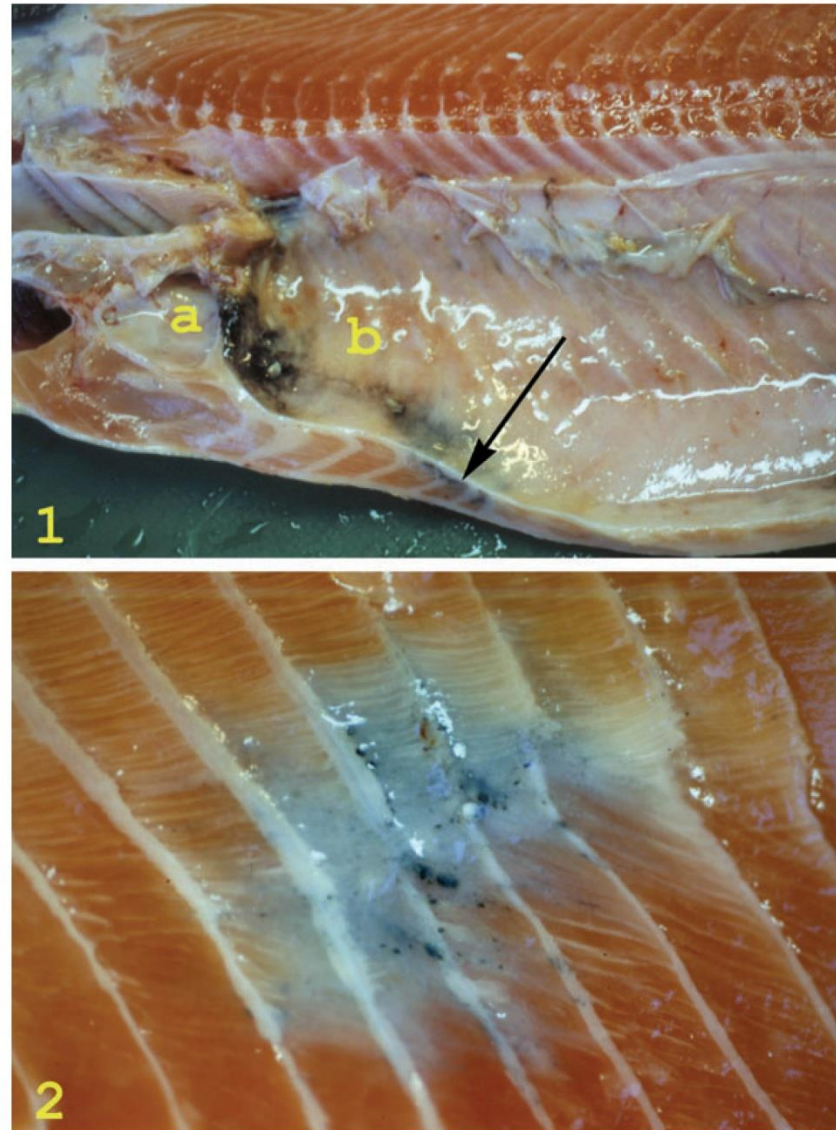


# Melanin and melanisation

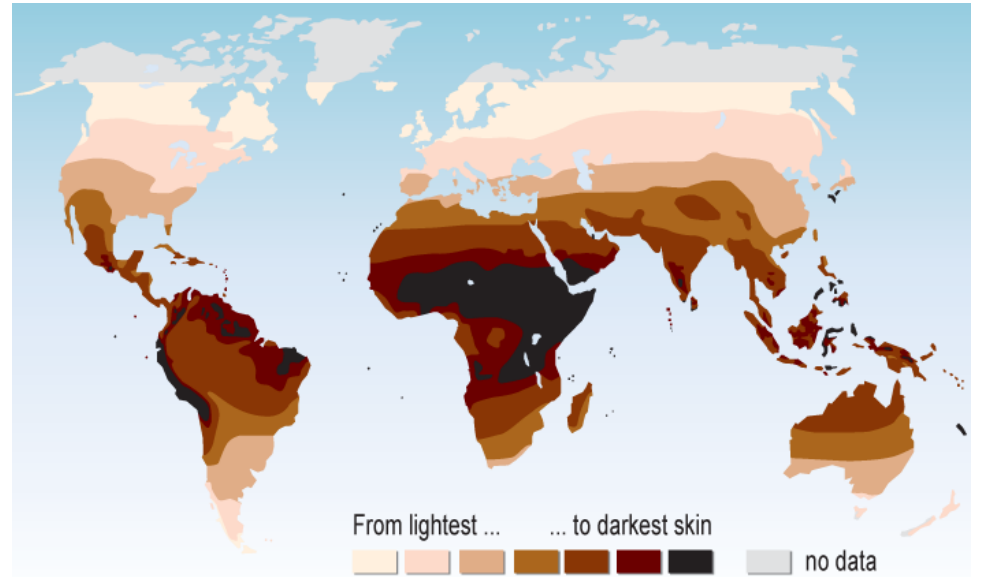
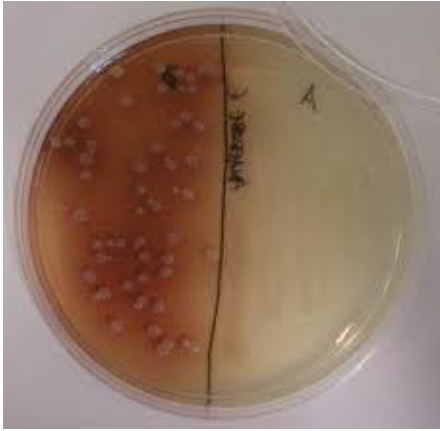


Erling Olaf Koppang  
Norges veterinærhøgskole  
Oslo



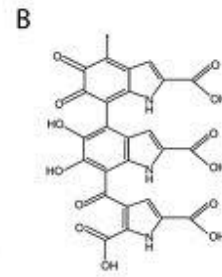
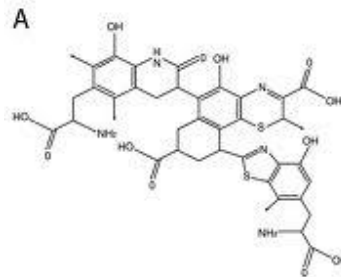
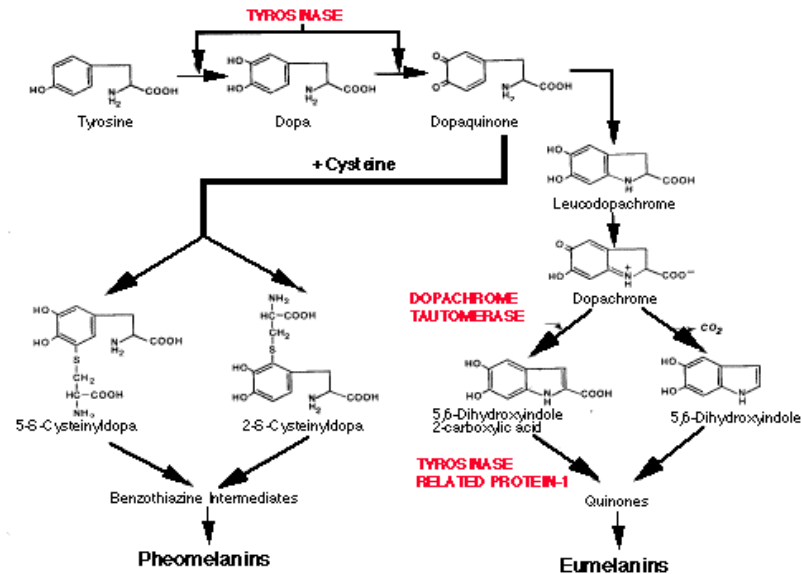
**Figure 1** Gross pathological changes in the carcass of an Atlantic salmon. The pericardial cavity (a) is normal, but severe melanization is apparent in the abdominal cavity (b). Melanized musculature subjacent to the peritoneum is seen on the cut surface (arrow).

**Figure 2** A melanized area in the musculature of an Atlantic salmon. The peritoneum is removed and darker foci are seen in a dark to grey area involving five myosepta. The lesion is situated laterally in the fish, covering the area of the lateral organ. Note the contraction in the musculature, disrupting the curves of the intramuscular septa.

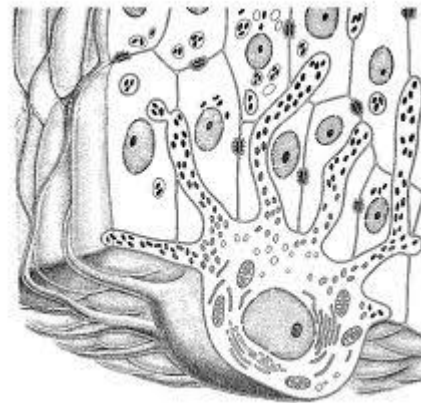
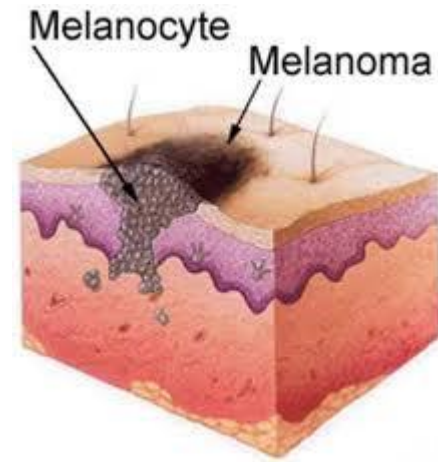
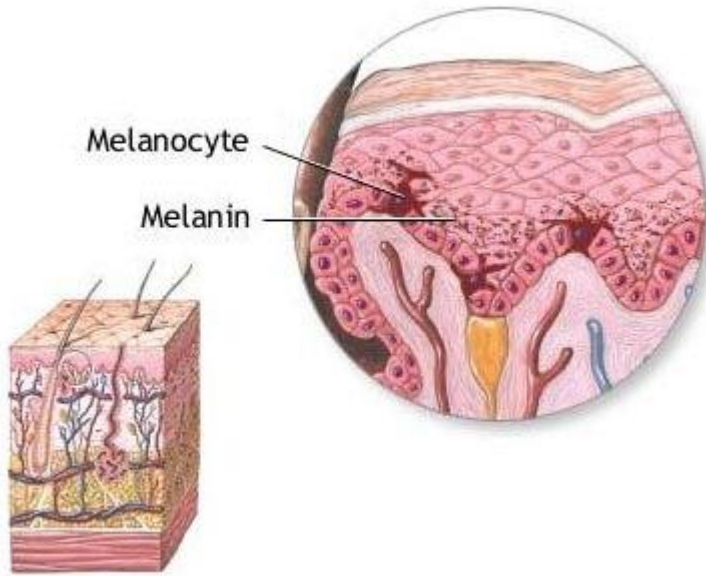


# What is melanin?

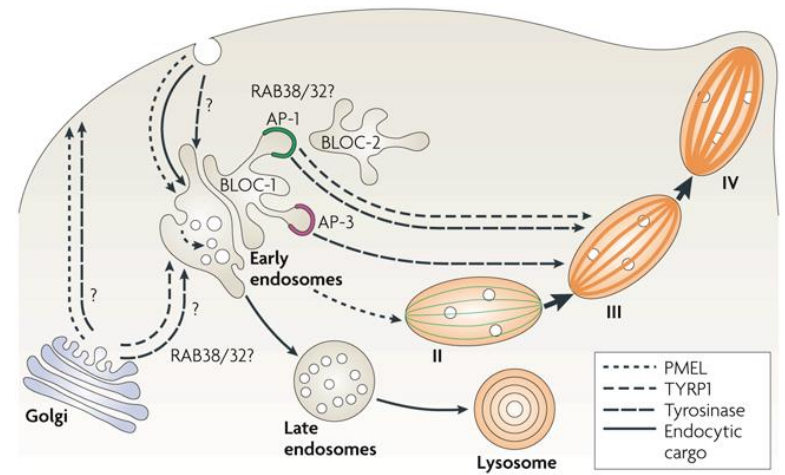
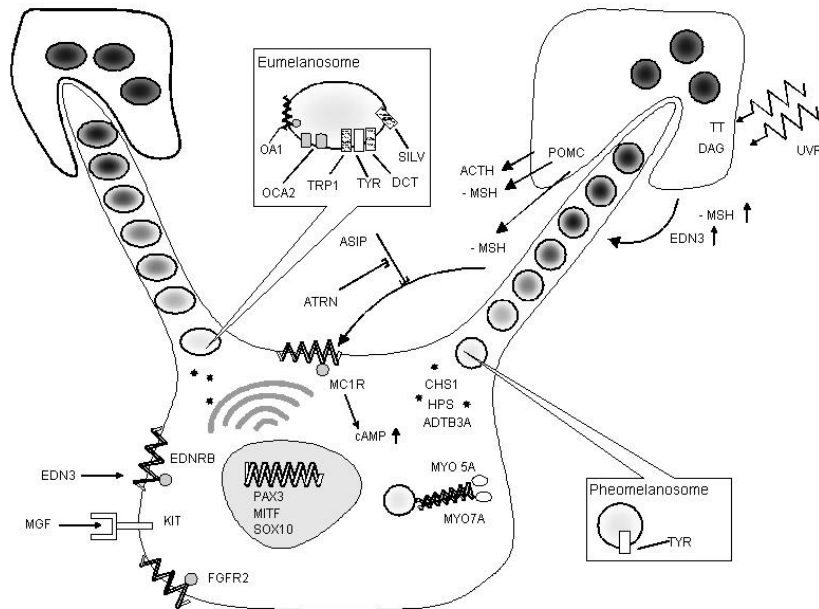
## The Melanin Chemical Pathway



# Where is melanin formed?




# Melanosome: the intracellular melanin producer



# What are the functions of melanin?



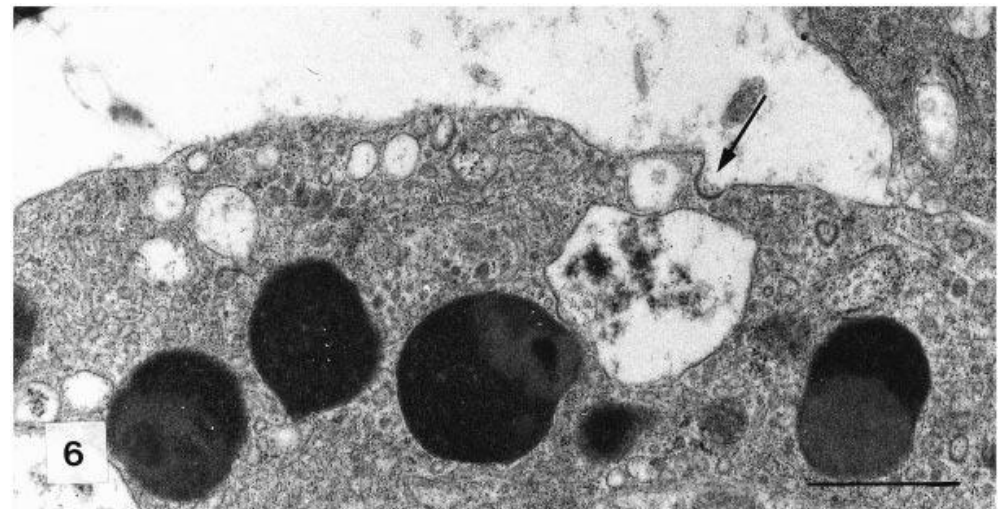
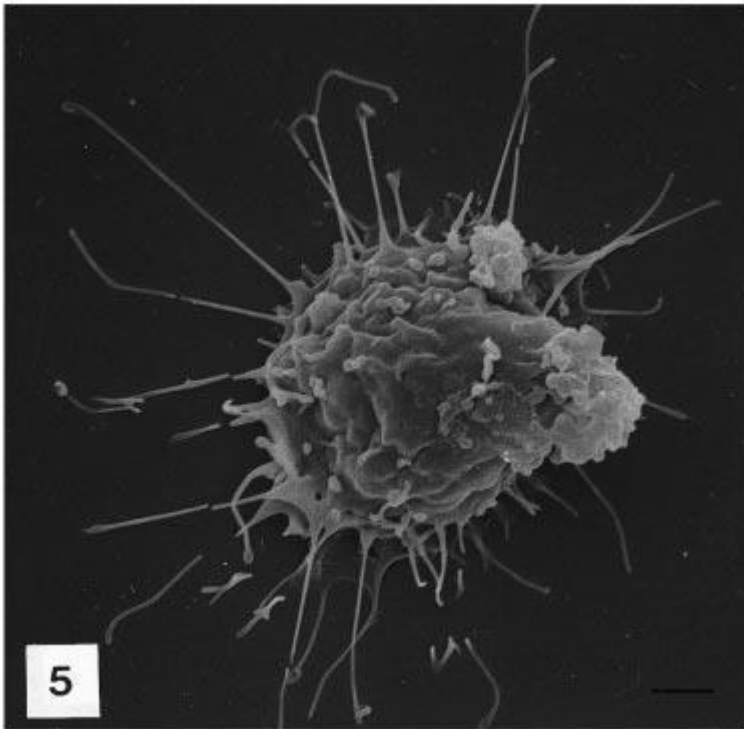
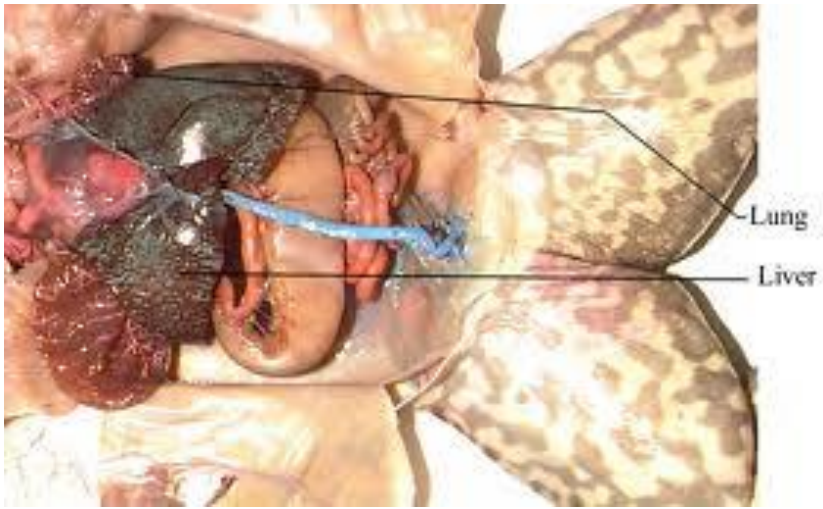






Giovanni Sichel – Universitetet i Catania





# Giovanni Sichel and co-workers:

- Melanin production in vertebrates is not exclusively confined to cells originating from the ectoderm.
- Kupffer cells in amphibian liver may synthesise melanin
- Kupffer cells derive from mesenchyme
- Conclusion: Populations of immune cells may synthesise melanin (contrast to mammals)

## Vaccine-associated granulomatous inflammation and melanin accumulation in Atlantic salmon, *Salmo salar* L., white muscle

E O Koppang<sup>1</sup>, E Haugarvoll<sup>1</sup>, I Hordvik<sup>2</sup>, L Aune<sup>1</sup> and T T Poppe<sup>1</sup>

<sup>1</sup> Department of Basic Sciences and Aquatic Medicine, Norwegian School of Veterinary Science, Oslo, Norway  
<sup>2</sup> Department of Fisheries and Marine Biology, HiB, University of Bergen, Norway

### Abstract

The purpose of this study was to investigate the nature of variably sized pigmented foci encountered in fillets of farmed Atlantic salmon, *Salmo salar* L. The material was sampled on the filler production line and on salmon farms from fish with an average size of 3 kg from various producers. The fish had been routinely vaccinated by injection. Gross pathology, histology, immunohistochemistry using antisera against major histocompatibility complex (MHC) class II  $\beta$  chain and transmission electron microscopy (TEM) were used to characterize the changes. Macroscopically, melanized foci were seen penetrating from the peritoneum deep into the abdominal wall, sometimes right through to the skin, and also embedded in the caudal musculature. Histological investigation revealed muscle degeneration and necrosis, fibrosis and granulomatous inflammation containing varying numbers of melano-macrophages. Vacuoles, either empty or containing heterogeneous material, were frequently seen. The presence of abundant MHC class II<sup>+</sup> cells indicated an active inflammatory condition. TEM showed large extracellular vacuoles and leucocytes containing homogeneous material of lipid-like appearance. The results showed that the melanized foci in Atlantic salmon fillet resulted from an inflammatory condition probably induced by vaccination. The described condition is not known in wild salmon and in farmed salmon where injection vaccination is not applied.

**Correspondence:** Trygve T Poppe, Department of Basic Sciences and Aquatic Medicine, Norwegian School of Veterinary Science, Ullevålsveien 72, Box 8148 Dep., 0333 Oslo, Norway (e-mail: trygve.poppe@vetinst.no)

**Keywords:** Atlantic salmon, inflammation, melano-macrophage, major histocompatibility complex class II, mineral oil, vaccine.

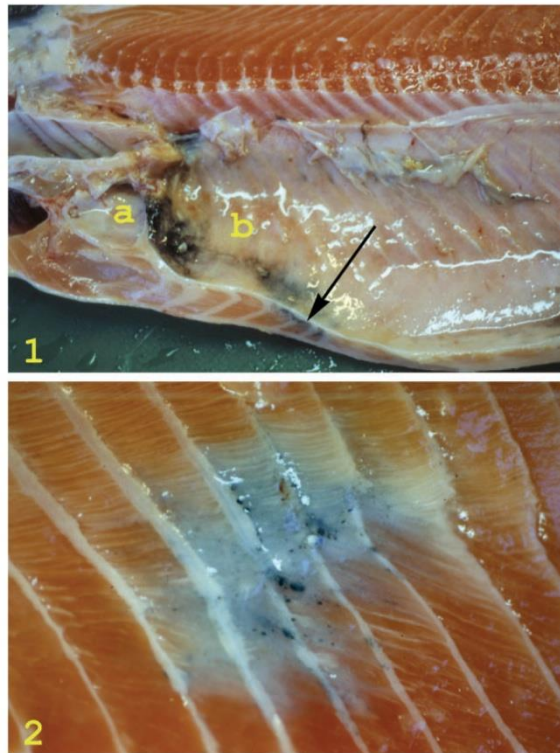
### Introduction

Various pathological conditions may be associated with abnormal pigmentation in tissues and organs. Such pigments may either be of exogenous or endogenous origin. Endogenous pigments include derivatives of lipids, haemoglobin, porphyrins and melanin. The term melanosis is used to describe the presence of melanin in abnormal locations (Thomson 1984). In vertebrates, melanin is synthesized by melanocytes and organized in melanosomes, which are lysosome-related intracellular organelles (Orlov 1995; Raposo, Favier, Soorvogel & Marks 2002). Mammalian melanocytes originate from the embryonic neural tube (Salmón & Kitchell 2003) and it has been observed that such cells can migrate into inflamed tissue (Thomson 1984).

Inflammatory reactions and tissue regeneration in salmonids seem similar to those of mammals (Finn & Nielson 1971), but have in addition been associated with the involvement of so-called melano-macrophages (Roberts 1975; Agius & Roberts 2003). The origin of melanosomes in melanin-containing viscera located cells in fish is not clear (Agius & Roberts 2003), but Sichel, Scalia, Mondio & Corsaro (1997) suggested that melanogenesis in poikilothermic vertebrates may occur in mesenchyme-derived cells of the haematopoietic lineage. Although teleost melano-macrophages have been ascribed macrophage-like properties, their functions and significance are

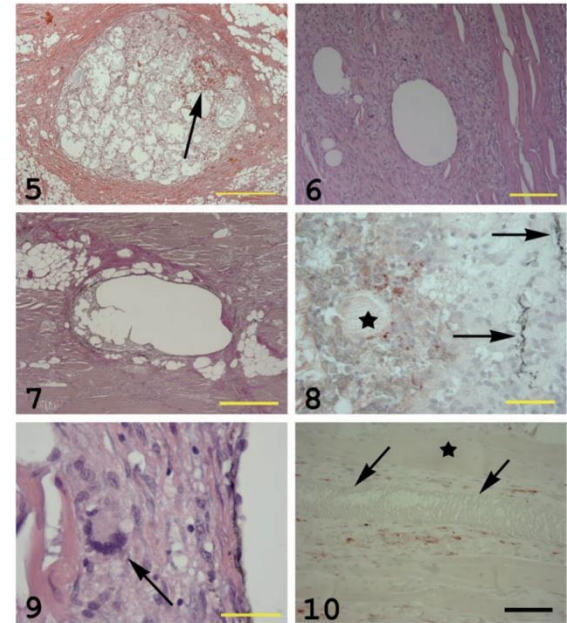
Journal of Fish Diseases 2005, 28, 13–22

E O Koppang et al. Vaccine-associated pathology in salmon muscle



**Figure 1** Gross pathological changes in the carcass of an Atlantic salmon. The pericardial cavity (a) is normal, but severe melanization is apparent in the abdominal cavity (b). Melanized musculature subjacent to the peritoneum is seen on the cut surface (arrow).

**Figure 2** A melanized area in the musculature of an Atlantic salmon. The peritoneum is removed and darker foci are seen in a dark to grey area involving five myosepta. The lesion is situated laterally in the fish, covering the area of the lateral organ. Note the contraction in the musculature, disrupting the curves of the intramuscular septa.



**Figure 5** A large vesicle embedded in an intermyotomal septum containing macrophage-like cells, debris and a fresh haemorrhage (arrow) (H&E, bar = 500  $\mu$ m).

**Figure 6** Empty vesicles surrounded by granulomatous tissue embedded in the white musculature. Note adjacent, seemingly unaffected muscle cells (H&E, bar = 200  $\mu$ m).

**Figure 7** Vesicles embedded in the white musculature surrounded by fibrogranulomatous tissue (red staining) (EVG, bar = 500  $\mu$ m).

**Figure 8** Reaction against oil (red staining) in a vesicle as shown in Fig. 5. Homogeneous masses (asterisk) and macrophage-like cells show positive reactions. Note the melano-macrophages in the vesicle wall (arrows) (oil red O, bar = 50  $\mu$ m).

**Figure 9** High magnification of the wall of a vesicle as seen in Fig. 6. The wall contains a multinucleated giant cell (MGC) (arrow), epithelioid-like cells, small vacuoles and is lined towards the lumen of the greater vesicle with melanosome-containing cells, probably swollen melano-macrophages (H&E, bar = 40  $\mu$ m).

**Figure 10** Muscle cells infiltrated with MHC class II<sup>+</sup> cells. One muscle cell is unaffected (asterisk). One fibre shows severe degeneration (arrowhead), whereas one is invaded by MHC class II<sup>+</sup> cells (red reaction) (MHC class II immunostain, haematoxylin counterstain, bar = 100  $\mu$ m).

## Melanogenesis and evidence for melanosome transport to the plasma membrane in a CD83<sup>+</sup> teleost leukocyte cell line

Erlend Haugarvoll<sup>1\*</sup>, Jim Thorsen<sup>1</sup>, Morten Laane<sup>2</sup>, Qirong Huang<sup>1</sup> and Erling Olaf Koppang<sup>1</sup>

<sup>1</sup>Institute of Basic Sciences and Aquatic Medicine, Norwegian School of Veterinary Science, Ullevålsveien 72, PO Box 8146 Dep., 0033 Oslo, Norway

<sup>2</sup>Institute of Molecular Bioscience, University of Oslo, 0316 Oslo, Norway

\*Address correspondence to Erlend Haugarvoll, e-mail: erlend.haugarvoll@veths.no

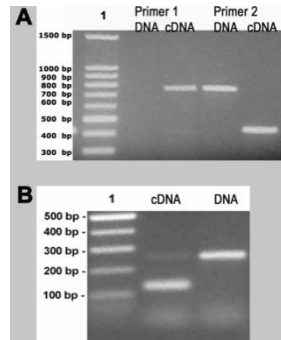
### Summary

Key words: CD83/dendritic cell/endosomal pathway/macrophage/melanogenesis/melanomacrophage/teleost

Received 1 April 2005, revised and accepted for publication 14 December 2005

### Introduction

Melanins are complex polymeric pigments, which are formed by a wide variety of living organisms ranging from fungi and bacteria to higher vertebrates (Margalith, 1992; Orlov, 1995; Raposo et al., 2002). Common for

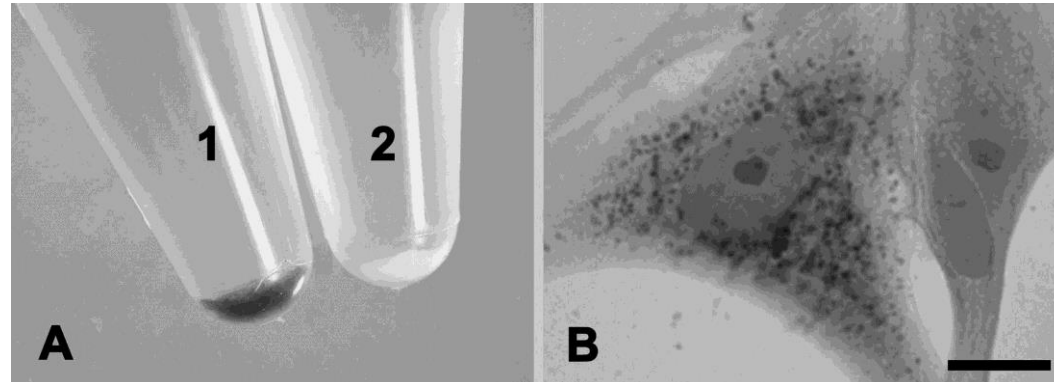


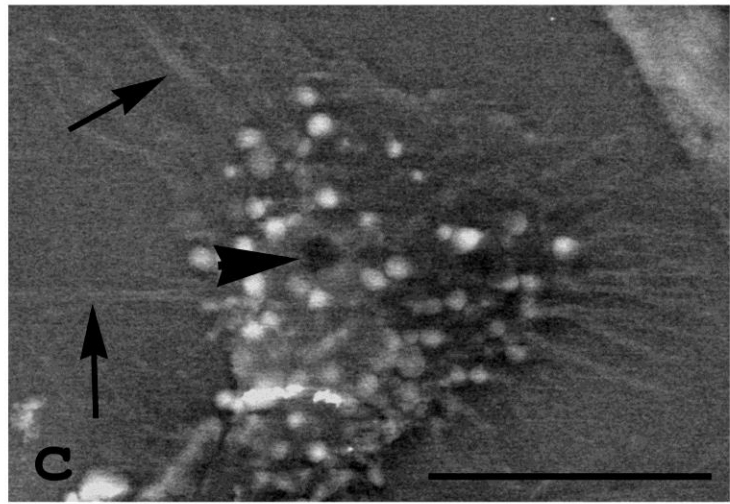
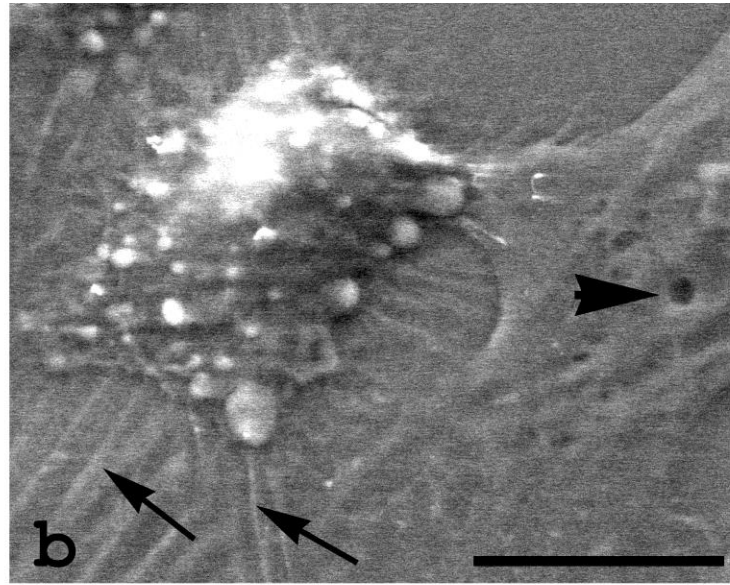
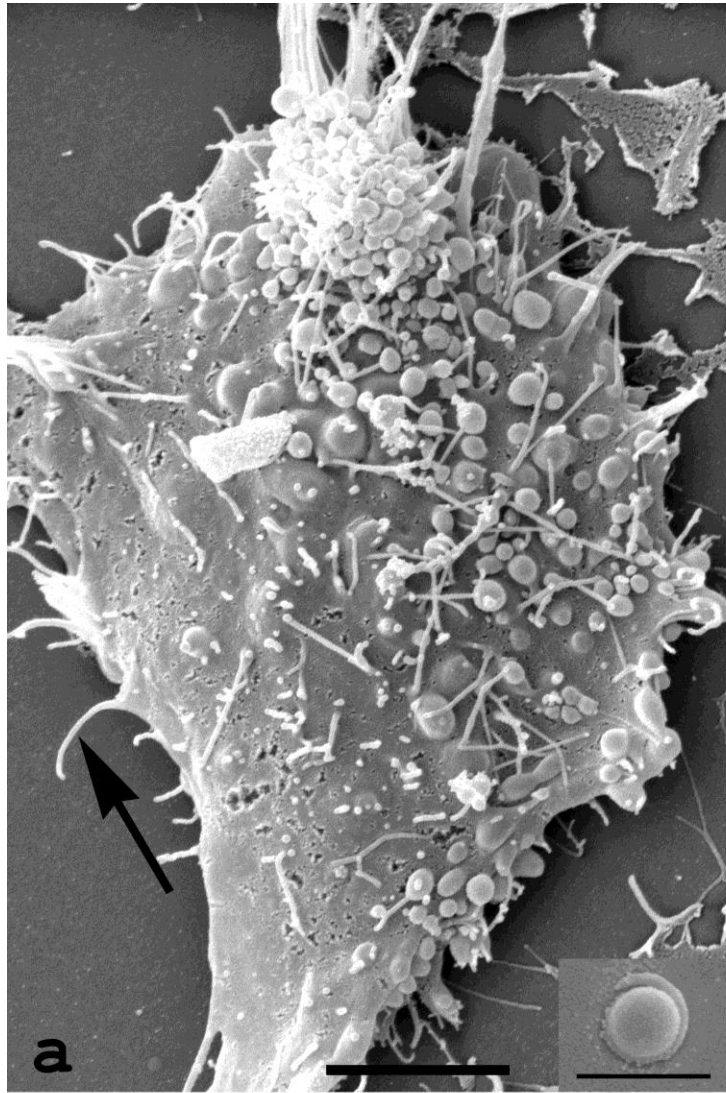
- Primer pairs recognising a fish CD83 homolog

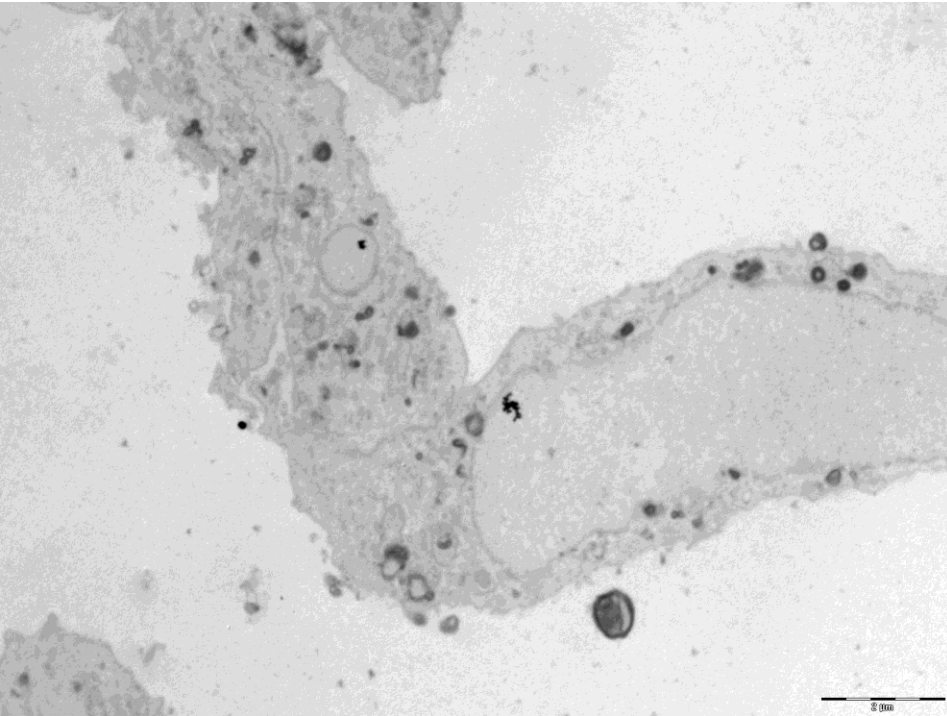
- Primer pair detecting Dct/TRP-2

- A; 0,1 mM PTU inhibit tyrosinase dopachrome production from L-DOPA

- B; a few long cultured cells showed melanin reduction potential

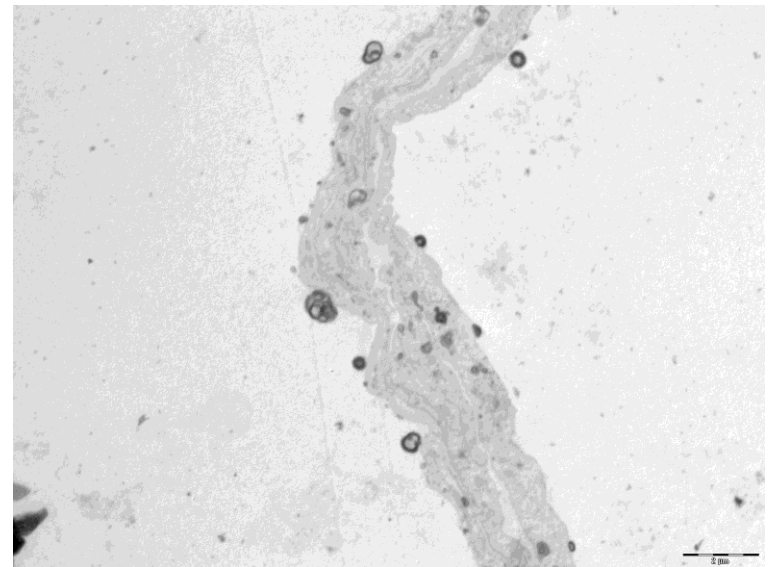






Haugarvoll et al. Pigment Cell Res  
2006;19:214-225

Thorsen et al. Pigment cell Res  
2006;19:327-336



# Isolation of the Atlantic salmon tyrosinase gene family reveals heterogenous transcripts in a leukocyte cell line

Jim Thorsen\*, Bjørn Høyheim and Erling O. Koppang

Institute of Basic Sciences and Aquatic Medicine, Norwegian School of Veterinary Science, Oslo, Norway  
\*Address correspondence to Jim Thorsen, e-mail: jim@jim.no

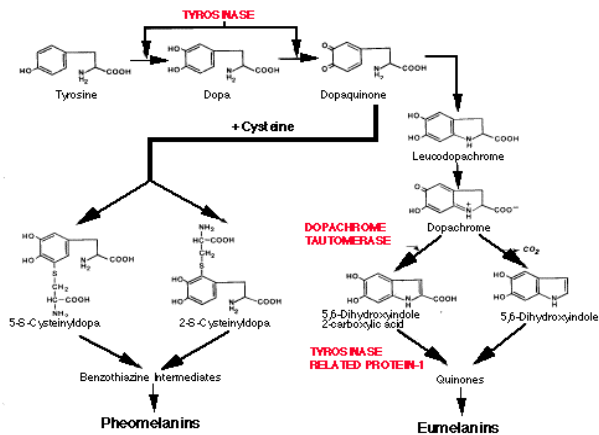
## Summary

In ectothermic vertebrates, visceral organs harbor melanin-containing cells. Their ability as pigment producers is nevertheless disputed. To address expression of the key genes for melanogenesis in Atlantic salmon (*Salmo salar*), a tyrosinase-positive leukocyte cell line (SHK-1) and skin were used to obtain full-length tyrosinase (Tyr), tyrosinase-like protein-1 (Tyrp1), and dopachrome tautomerase (Dct) mRNA transcripts. In the SHK-1 cells, two different Tyrp1 transcripts were identified, one lacking exon 1. However, only the full-length version of Tyrp1 was identified in the skin. Sequen-

## Introduction

The pigimentary system of vertebrates has predominantly been addressed in cells derived from the embryonic neural tube ectoderm (Boissy and Nordlund, 1997). Pigmented cells or melanocytes in the normal adult mammal occur in the skin, uvea, retina, meninges, the inner ear, and the Harderian gland (Boissy, 1998). Such cells are characterized by their ability to synthesize melanin, a process confined within discrete organelles termed melanosomes. Melanosomes share several properties with lysosomes (Orlow, 1995; Raposo et al., 2002), and any melanocyte precursor is defined as a melanoblast (Fitzpatrick et al., 1966). The functions of melanin are not only restricted to absorb, scatter and reflect light, but also include binding of metal ions and organic cations, and acting as antioxidants and scavengers of free reactive radicals (Margalith, 1992; Sarna and Swartz, 1998). Interestingly, increasing information link the functions of the pigimentary and immune systems (Mackintosh, 2001; Raposo et al., 2002).

## The Melanin Chemical Pathway



Thorsen et al.

**A**

**Tyr**

```
Tl_Tyr 1  ...RRITCAEMLELLELYALGGPFFPSENHGNTIETRPPGPRGADVAALAMNDFEELGSDPDRDFFIRHREERRRNATRETIICRRCQDGREGRVY108
Dr_Tyr 1  ...SHLLE...FFFLGLFSBLOQFPAVITLSPVYQSHRPGHPRVLRDGGDGGQDSQDFVADHREANVWYVCGDAGNAGNADNPPYVCGDAGNAGNADNPPYVCGDAGNAGNADNPPY110
Om_Tyr1 1  ...IPELILHGVVFEGDGFBDGFPLDTLTAALGDSDFVDVDSAGDAGHSDHSDGSHRVEDGLNLELHSHDPSDELDNRVLYNTGCGANMDDNDCGQDL...110
Om_Tyr2 1  ...IPELILHGVVFEGDGFBDGFPLDTLTAALGDSDFVDVDSAGDAGHSDHSDGSHRVEDGLNLELHSHDPSDELDNRVLYNTGCGANMDDNDCGQDL...110
Sl_Tyr 1  ...HVEELVVLGLOMLFERSGVGDEFFPANTALANTDGDHPSDAGDAGAHSDHSDGSHRVEDGLNLELHSHDPSDELDNRVLYNTGCGANMDDNDCGQDL...110
```

**B**

**Tyrp1**

```
Tl_Tyrp1 1 MFARCVFLAASAVVRADPFDGVTYFVRSQDCDPFFPFDGPGDAGSTGRQCVLTVBAPRSPDPYDHRDRDRWPAFRNSDCGNNGEADCRH106
Dr_Tyrp1 1 HXKVCVLVAVVRADPFDGVTYFVRSQDCDPFFPFDGPGDAGSTGRQCVLTVBAPRSPDPYDHRDRDRWPAFRNSDCGNNGEADCRH106
Sl_Tyrp1 1 MWKVCVLVAVVRADPFDGVTYFVRSQDCDPFFPFDGPGDAGSTGRQCVLTVBAPRSPDPYDHRDRDRWPAFRNSDCGNNGEADCRH106
Om_Tyrp1 1 ...P...I...I...106
```

**C**

**Dct**

```
Tl_Dct 1 MMTALGVYFLFLVWVKATGADPFRVCTVEGLLKDGPALSDPAPNCGEETDGGDVSVDHSPGWDGFLRNVDDEERWTKFFNTGTCGTGAMFNAYG104
Dr_Dct 1 MKRFVEMICFQGYMLSEADPFRVCTVEGLLKDGPALSDPAPNCGEETDGGDVSVDHSPGWDGFLRNVDDEERWTKFFNTGTCGTGAMFNAYG104
Om_Dct 1 MKAALVGLVYVWVWSDGKATGADPFRVCTVEGLLKDGPALSDPAPNCGEETDGGDVSVDHSPGWDGFLRNVDDEERWTKFFNTGTCGTGAMFNAYG104
```





[Biochem Cell Biol.](#) 2012 Dec;90(6):769-78. doi: 10.1139/o2012-033. Epub 2012 Nov 20.

**Melanogenesis in visceral tissues of *Salmo salar*. A link between immunity and pigment production?**

[Arciuli M](#), [Fiocco D](#), [Cicero R](#), [Maida I](#), [Zanna PT](#), [Guida G](#), [Horsberg TE](#), [Koppang EO](#), [Gallone A](#).

**Source**

Sezione di Biologia Medica, Dipartimento di Scienze Mediche di Base, Neuroscienze ed Organi di Senso, Università degli Studi di Bari, Policlinico-Piazza Giulio Cesare, 70124 Bari, Italy.



Contents lists available at SciVerse ScienceDirect

## Fish & Shellfish Immunology

journal homepage: [www.elsevier.com/locate/fsi](http://www.elsevier.com/locate/fsi)



# Pigment-producing granulomatous myopathy in Atlantic salmon: A novel inflammatory response

Hilde A.S. Larsen<sup>a</sup>, Lars Austbø<sup>b</sup>, Turid Mørkøre<sup>c</sup>, Jim Thorsen<sup>d</sup>, Ivar Hordvik<sup>e</sup>, Uwe Fischer<sup>f</sup>, Emilio Jirillo<sup>g</sup>, Espen Rimstad<sup>h</sup>, Erling O. Koppang<sup>a,\*</sup>

<sup>a</sup> Section of Anatomy and Pathology, Institute of Basic Science and Aquatic Medicine, Norwegian School of Veterinary Science, Ullevålsveien 72, PO Box 8146 Dep., 0033 Oslo, Norway

<sup>b</sup> Section of Genetics, Department of Basic Science and Aquatic Medicine, Norwegian School of Veterinary Science, Oslo, Norway

<sup>c</sup> Nofima Marin AS, Ås, Norway

<sup>d</sup> Section of Cancer Cytogenetics, Institute for Medical Informatics, Oslo University Hospital HF, Oslo, Norway

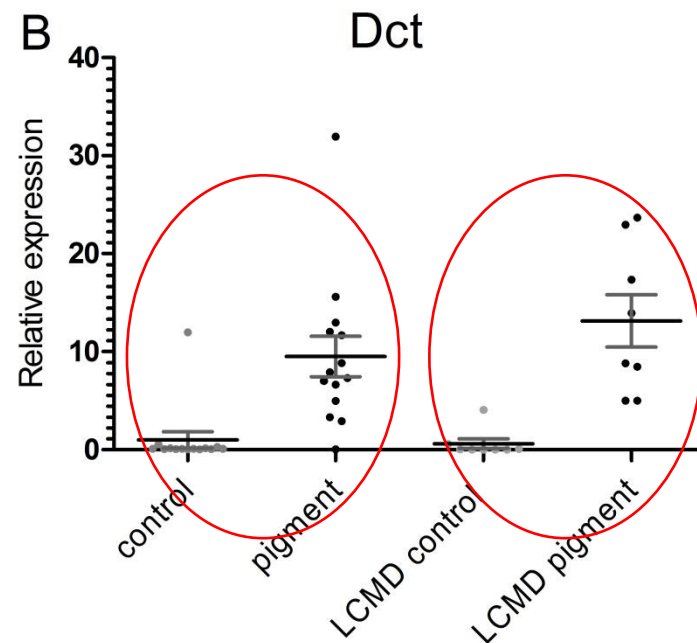
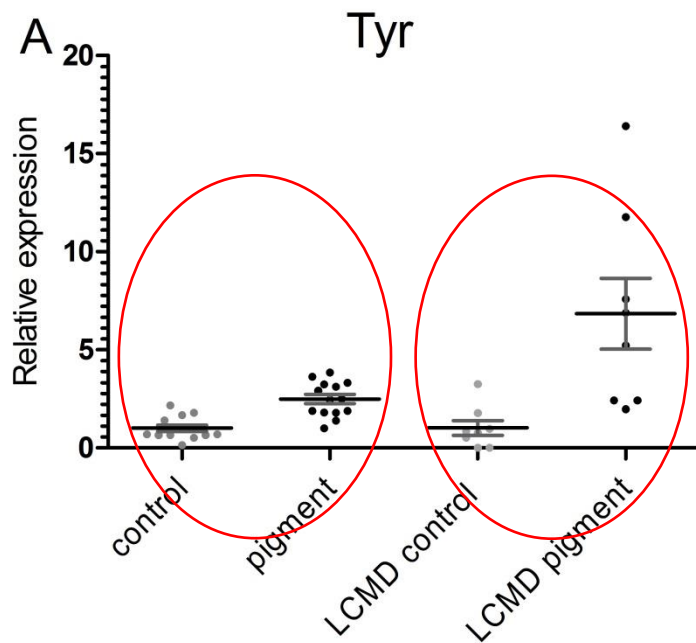
<sup>e</sup> Department of Biology, University of Bergen, Bergen, Norway

<sup>f</sup> Friedrich-Loeffler-Institut, Federal Research Institute for Animal Health, Institute of Infectology, Greifswald-Insel Riems, Germany

<sup>g</sup> Department of Immunology, Faculty of Medicine, University of Bari, Bari, Italy

<sup>h</sup> Section of Microbiology, Immunology and Parasitology, Department of Food Safety and Infection Biology, Norwegian School of Veterinary Science, Oslo, Norway

# Up-regulation of the tyrosinase gene family in the black spots



## **The effect of vaccination, ploidy and smolt production regime on pathological melanin depositions in muscle tissue of Atlantic salmon, *Salmo salar* L.**

H A S Larsen<sup>1</sup>, L Austbø<sup>2</sup>, A Nødtvedt<sup>3</sup>, T W K Fraser<sup>3</sup>, E Rimstad<sup>4</sup>, P G Fjellidal<sup>5</sup>, T Hansen<sup>5</sup> and E O Koppang<sup>1</sup>

1 Department of Basic Science and Aquatic Medicine, Section of Anatomy and Pathology, Norwegian School of Veterinary Science, Oslo, Norway

2 Department of Basic Science and Aquatic Medicine, Section of Genetics, Norwegian School of Veterinary Science, Oslo, Norway

3 Department of Production Animal Clinical Sciences, Norwegian School of Veterinary Science, Oslo, Norway

4 Department of Food Safety and Infection Biology, Section of Microbiology, Immunology and Parasitology, Norwegian School of Veterinary Science, Oslo, Norway

5 Institute of Marine Research, Matre Research Station, Matredal, Norway





Contents lists available at SciVerse ScienceDirect

## Developmental and Comparative Immunology

journal homepage: [www.elsevier.com/locate/dci](http://www.elsevier.com/locate/dci)



Transcription of the tyrosinase gene family in an Atlantic salmon leukocyte cell line (SHK-1) is influenced by temperature, but not by virus infection or bacterin stimulation



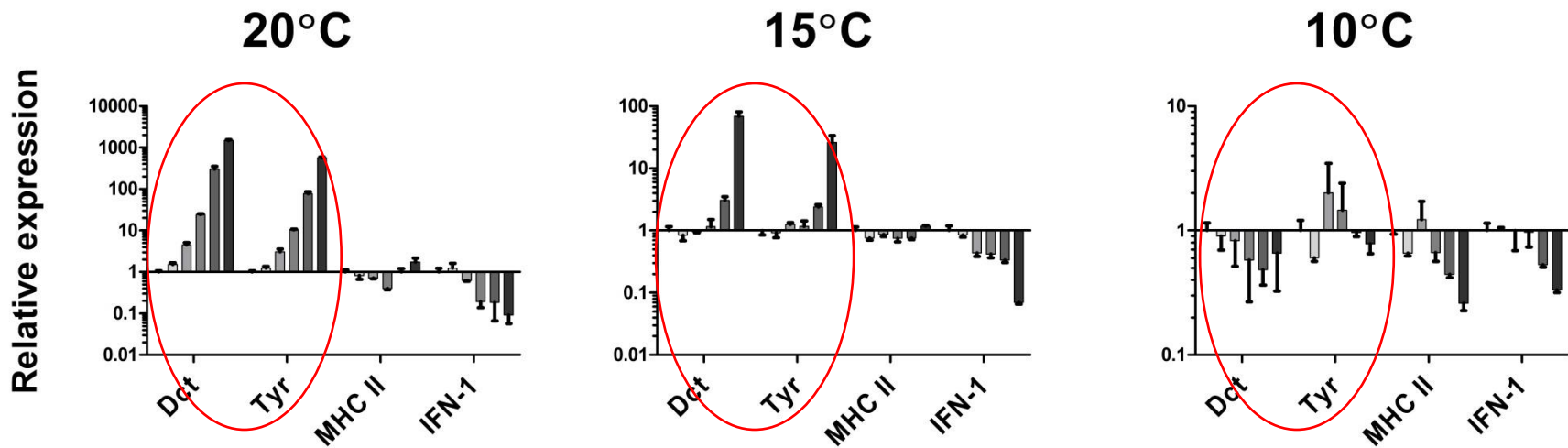
Hilde A.S. Larsen<sup>a</sup>, Lars Austbø<sup>b</sup>, Melanie König<sup>b</sup>, Henning Sørum<sup>c</sup>, Espen Rimstad<sup>c</sup>, Erling O. Koppang<sup>a,\*</sup>

<sup>a</sup> Section of Anatomy and Pathology, Department of Basic Science and Aquatic Medicine, Norwegian School of Veterinary Science, Oslo, Norway

<sup>b</sup> Section of Genetics, Department of Basic Science and Aquatic Medicine, Norwegian School of Veterinary Science, Oslo, Norway

<sup>c</sup> Section of Microbiology, Immunology and Parasitology, Department of Food Safety and Infection Biology, Norwegian School of Veterinary Science, Oslo, Norway

# Up-regulation of the tyrosinase gene family by temperature stimulation *in vitro*



Timeline for each gene

**Pathological pigmentation in the hearts of Atlantic salmon (*Salmo salar* L.) with cardiomyopathy syndrome**

Hilde A. S. Fagerland<sup>1</sup>, Lars Austbø<sup>2</sup>, Camilla Fritsvold<sup>3</sup>, Marta Alarcon<sup>3</sup>, Espen Rimstad<sup>4</sup>, Knut Falk<sup>3</sup>,

Torunn Taksdal<sup>3</sup> and Erling O. Koppang<sup>1,5</sup>

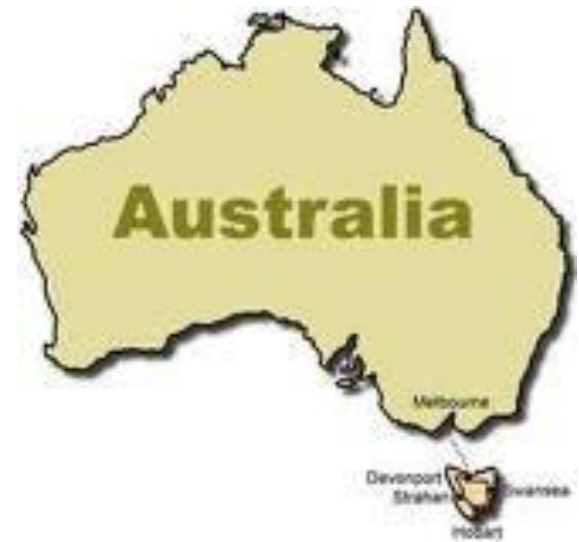<sup>1</sup>Section of Anatomy and Pathology, Department of Basic Science and Aquatic Medicine, Norwegian School of Veterinary Science, Oslo, Norway. <sup>2</sup>Section of Genetics, Department of Basic Science and Aquatic Medicine, Norwegian School of Veterinary Science, Oslo, Norway. <sup>3</sup> Norwegian Veterinary Institute, Oslo Norway. <sup>4</sup>Section of Microbiology, Immunology and Parasitology, Department Food Safety and Infection Biology, Norwegian School of Veterinary Science, Oslo, Norway.

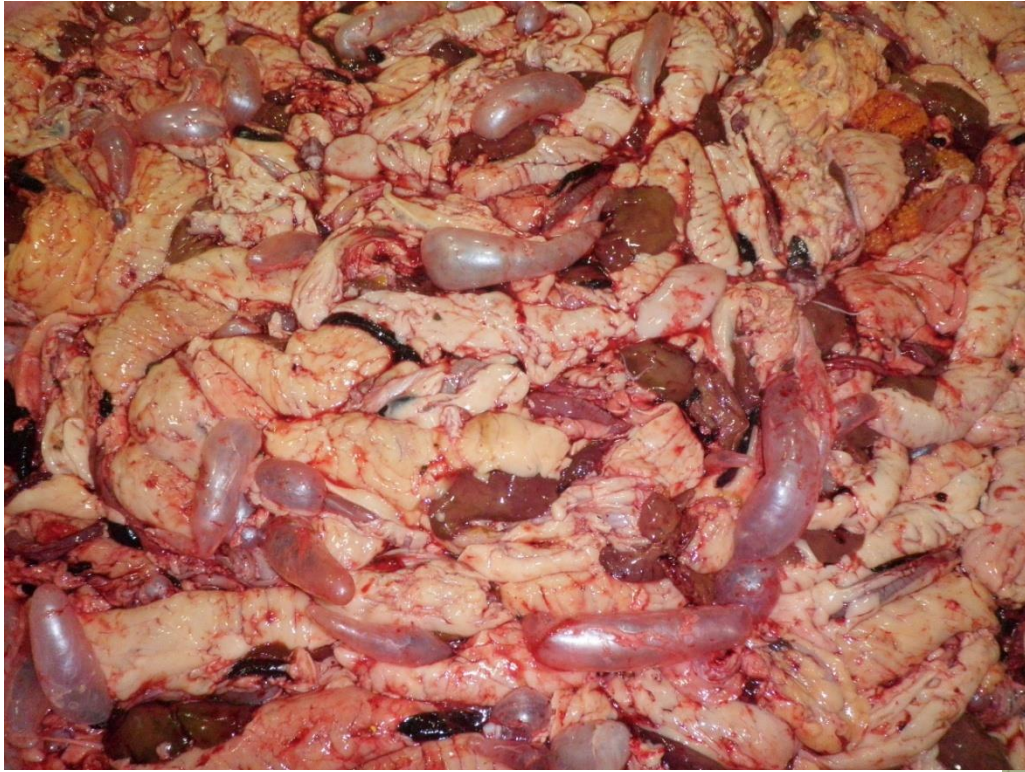

# Is melanin always melanin?









# Melanin-containing cells in normal and inflamed tissues



**Agnar Kvellestad**

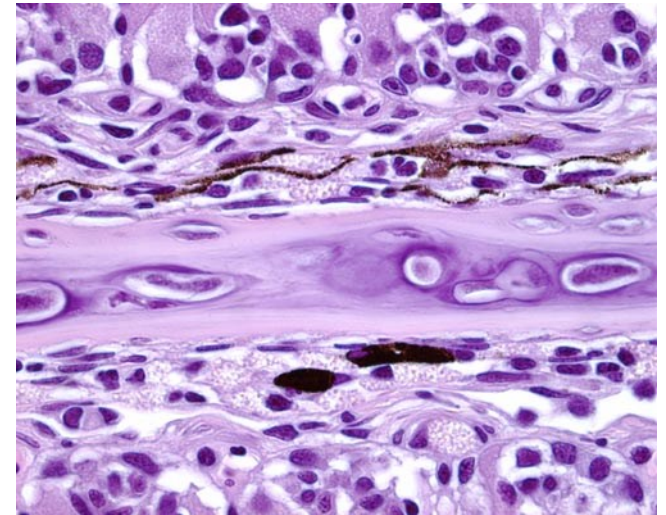
Norwegian School of Veterinary Science  
Department of Basic Sciences and Aquatic Medicine

# Melanin-containing cells

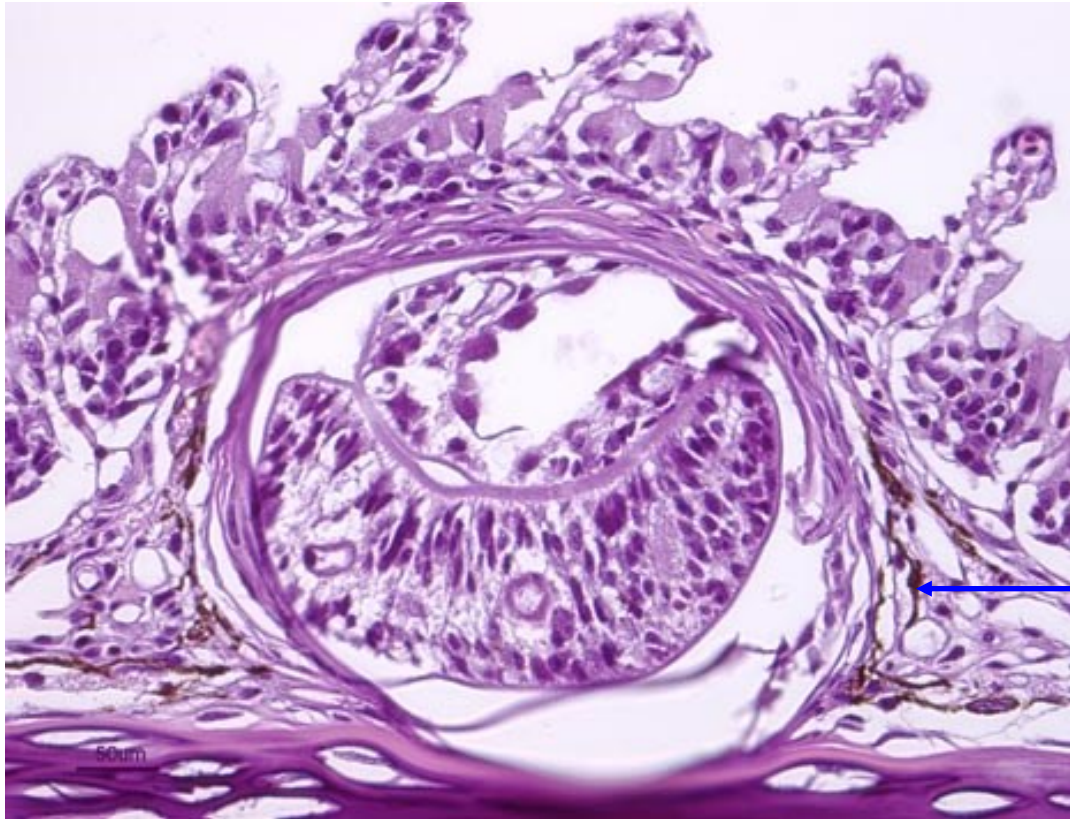
Normally present in the septum of gills



Occasionally seen in gill filaments  
– pathology?



## Immune and pigment systems

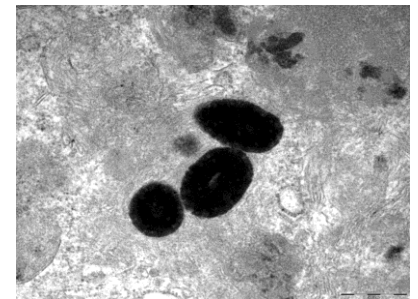
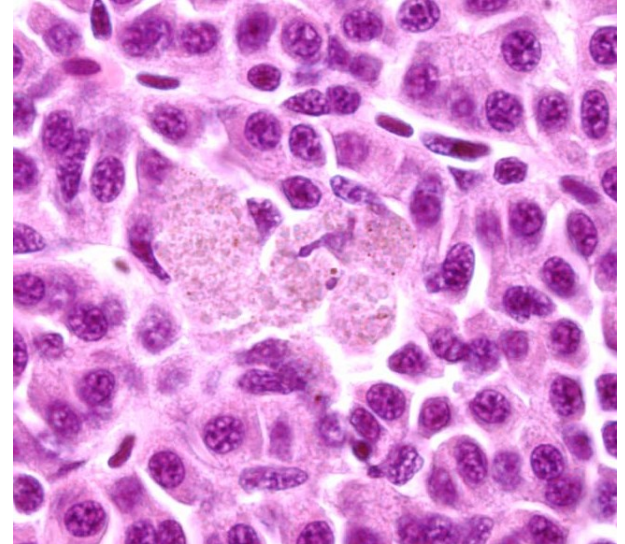
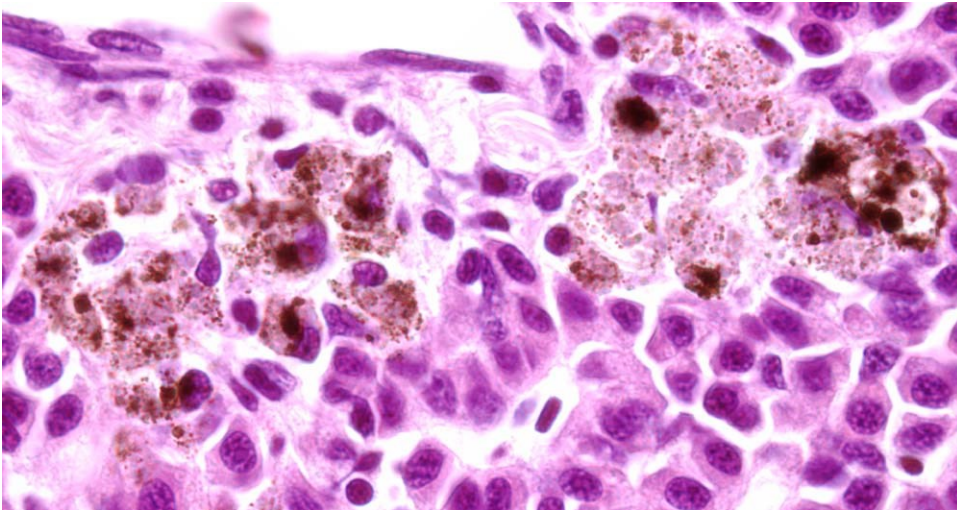


Encapsulated metacercariae of *Cryptocotyle lingua*, visible as black spots in gills and skin of salmon and marine fish

## Hepatitis:

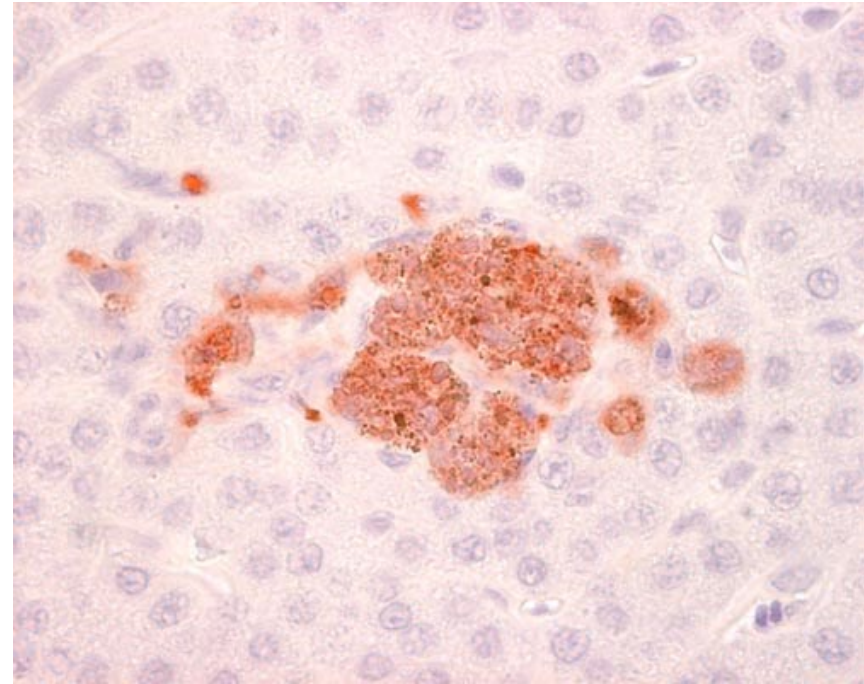
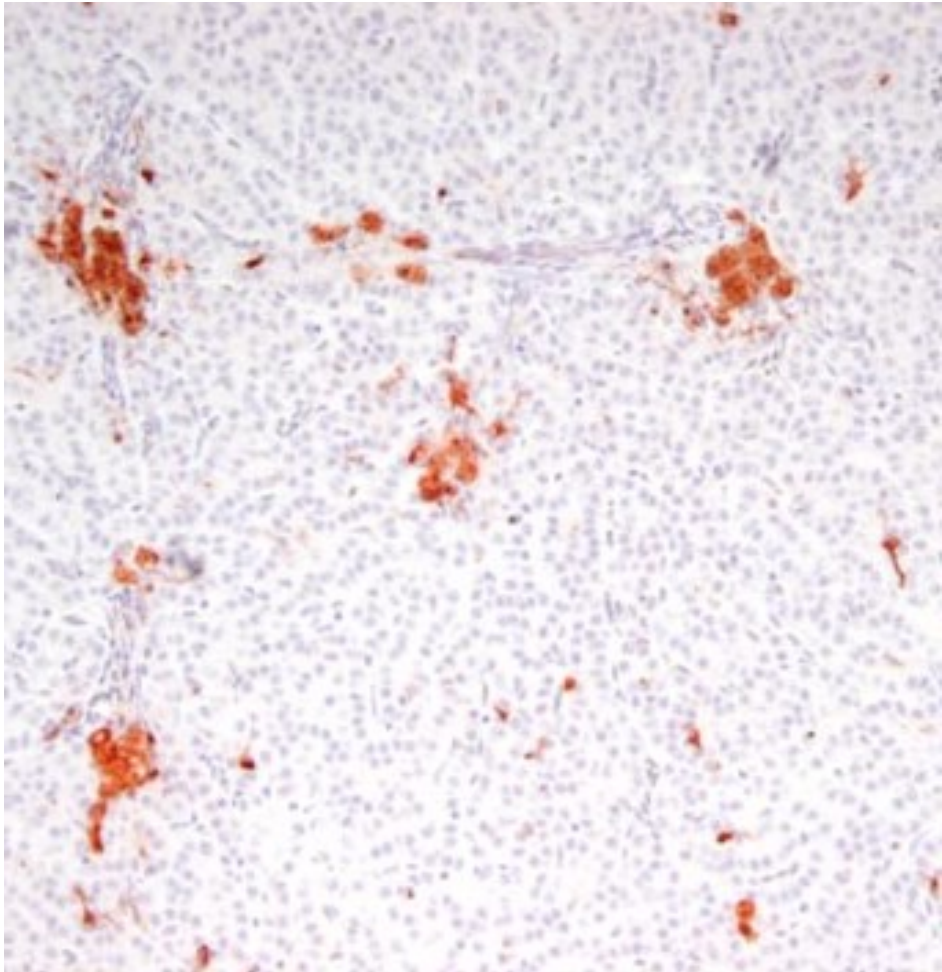
Macrophage-like cells may contain melanin-granules

De novo synthesis?



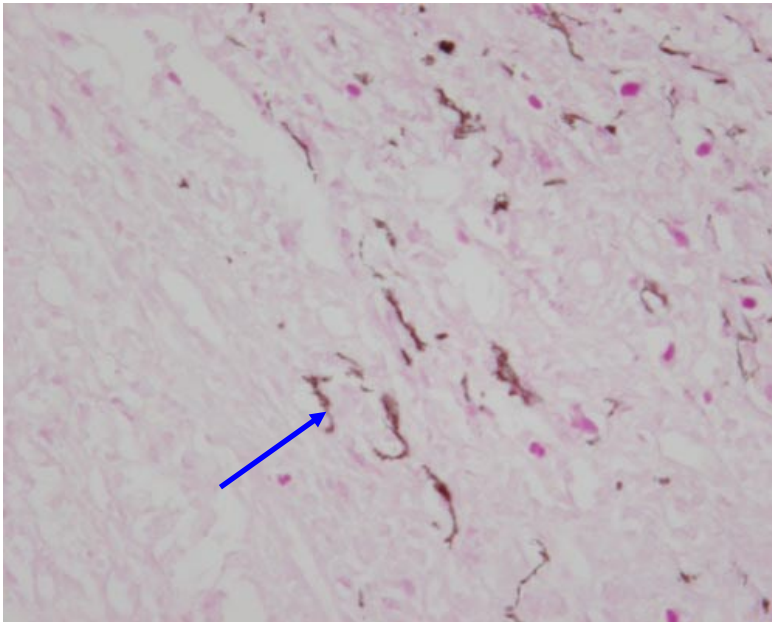


## MHC class II molecules in macro-phage like cells



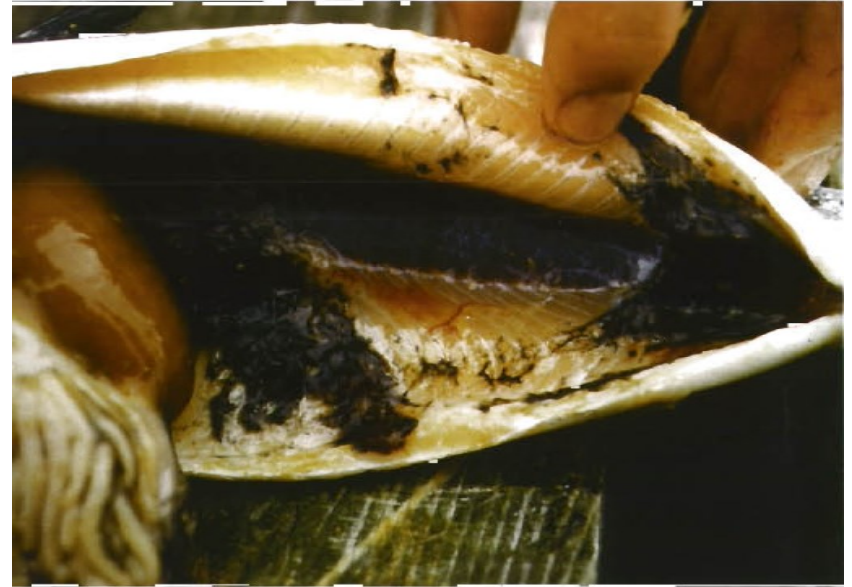Kvellestad & Koppang

## Chronic peritonitis following i.p. Injection of oil-adjuvanted vaccines



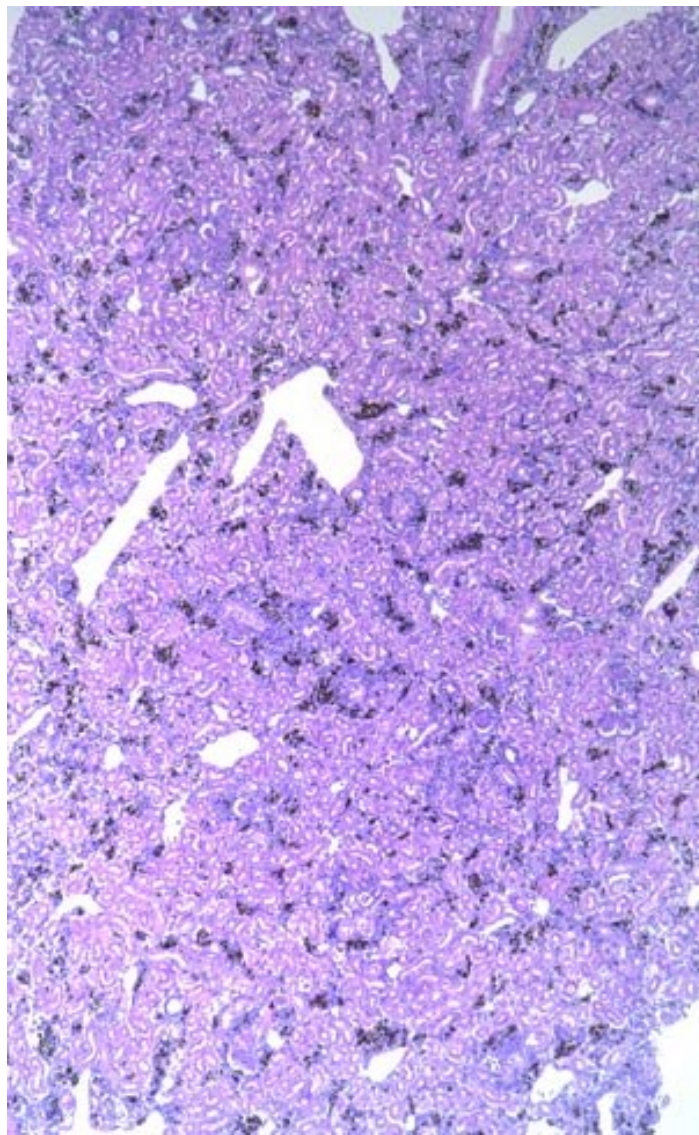
Elongated/flattened cells.

PAS stain. Photo: Agnar Kvellestad



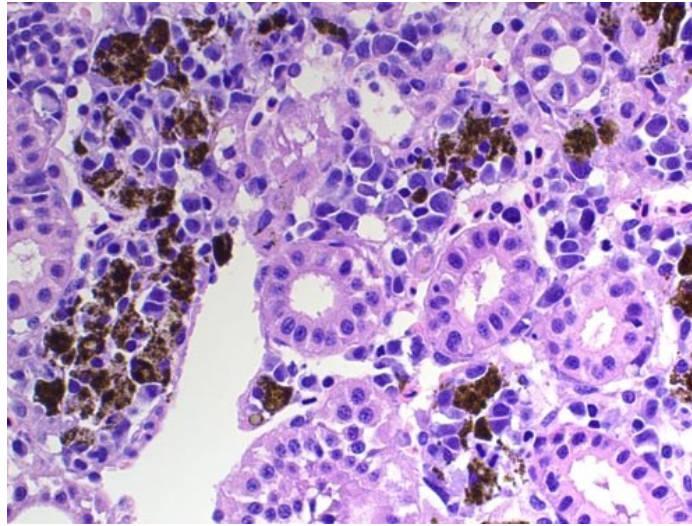
Poppe & Breck (1997): Pathology of Atlantic salmon *Salmo salar* intraperitoneally immunized with oil-adjuvanted vaccine. A case report. DAO 29: 219-226.

## Emaciated post-smolt



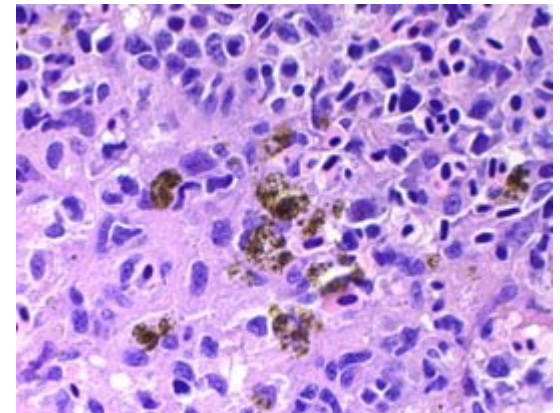
2005-09-0476-L6R-40x-Zeiss Axio 2013 NVH-nyre m rikeleg melanin

### Kidney

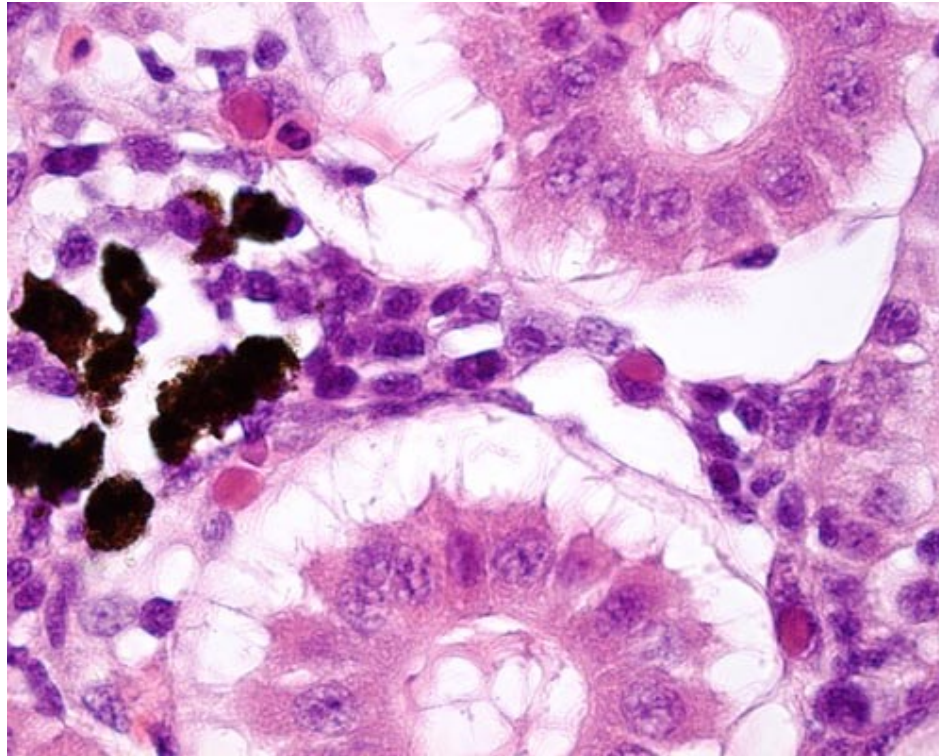


2005-09-0476-L6R-2komma5x-Zeiss Axio 2013 NVH-nyre m rikeleg melanin crop mm

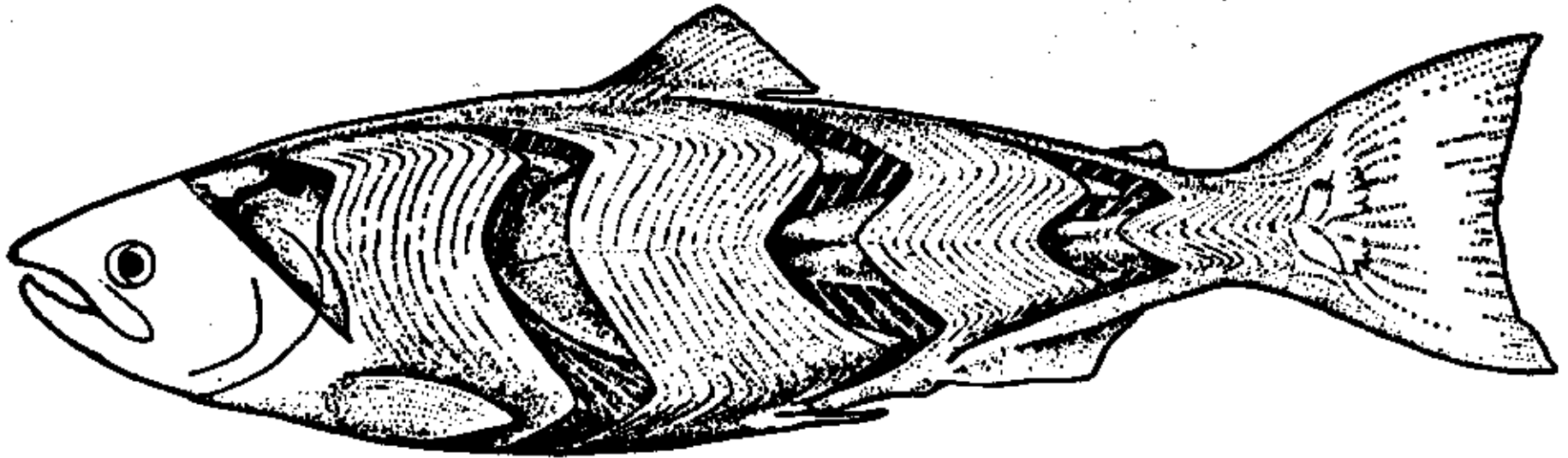
### Spleen



## Kidney with degradation of erythrocytes



## Anatomy of muscle



**Fig. 83. The axial musculature of a salmon. In four places a series of myomeres has been removed to show the complicated internal folding of these segmental structures. Within the body each W projects farther anteriorly or posteriorly than it does at the surface. The myoseptum horizontale is cutting the main, anterior-pointing W. (After Greene from Romer.) To p. 97, 98.**

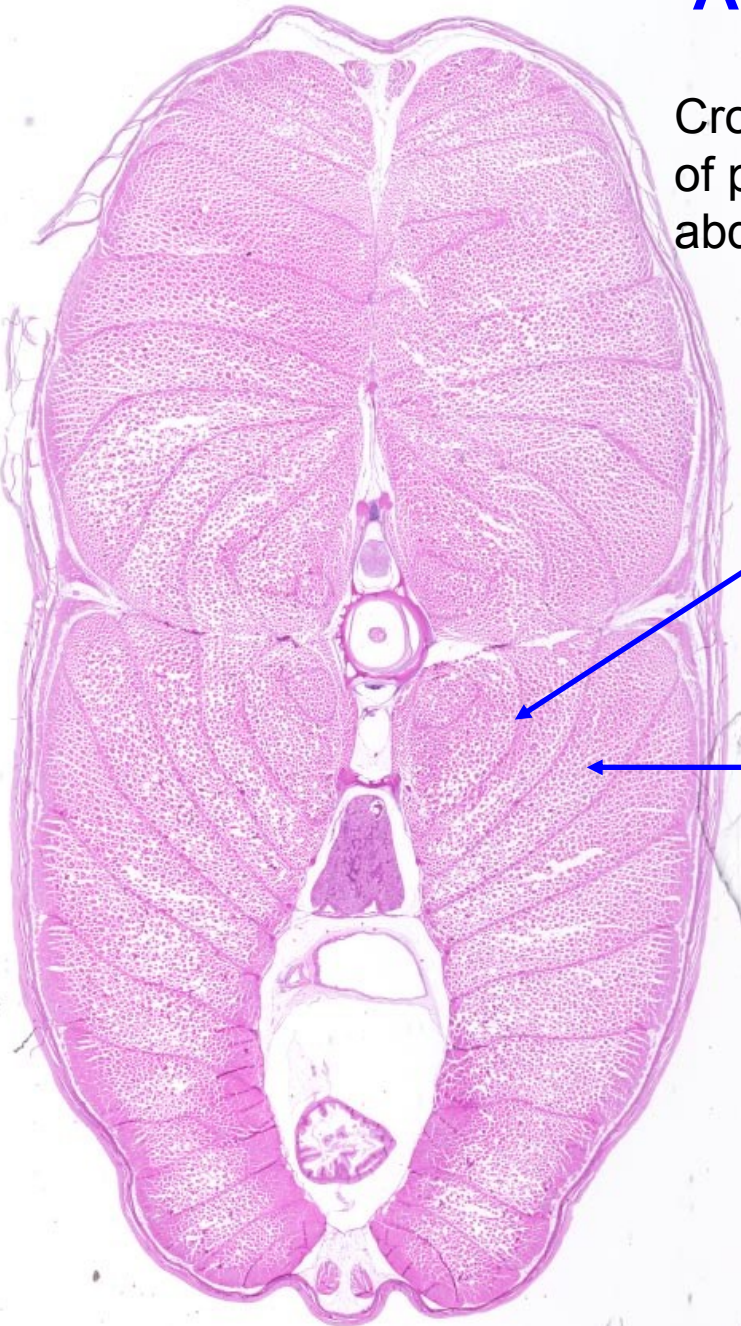
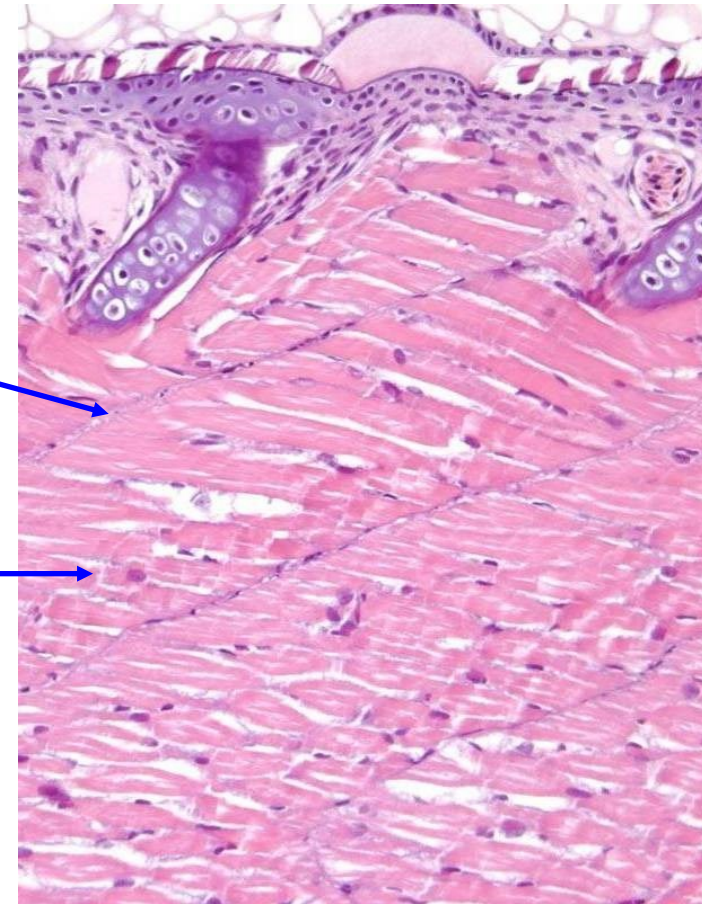
# Anatomy of muscle

Cross section  
of posterior  
abdomen

Longitudinal section

Myoseptum

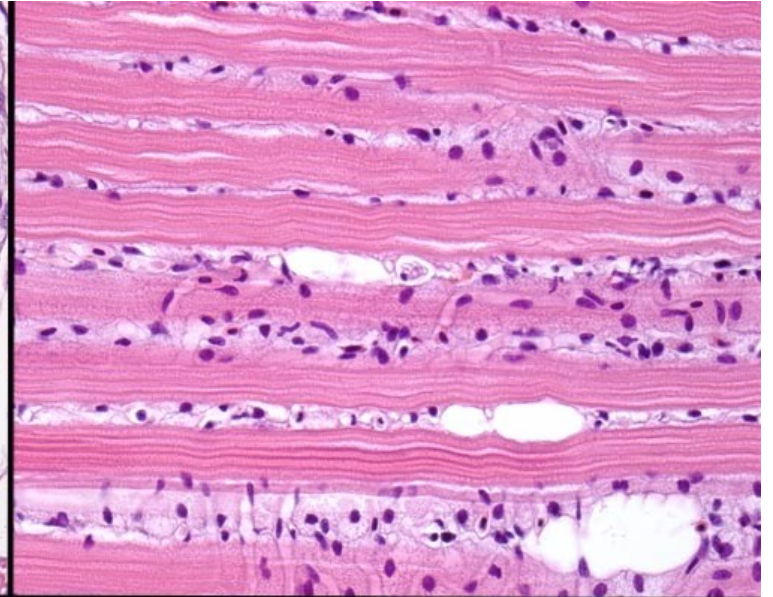
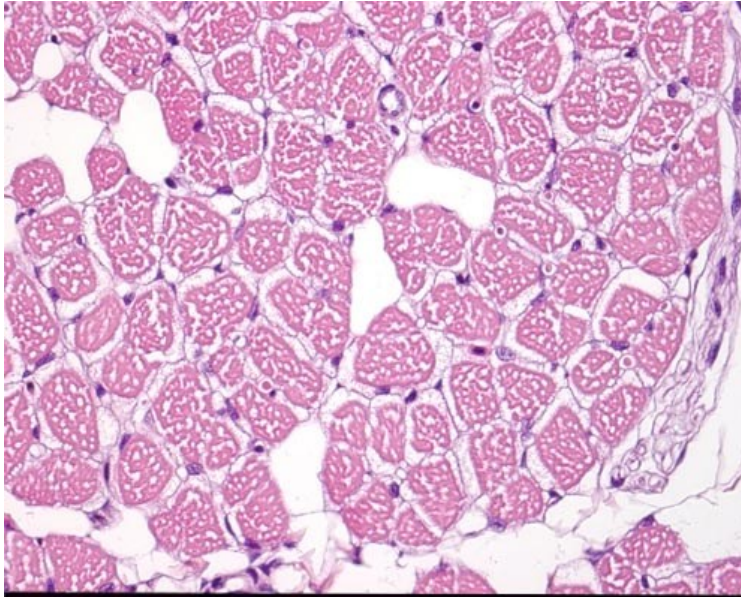
Myomere



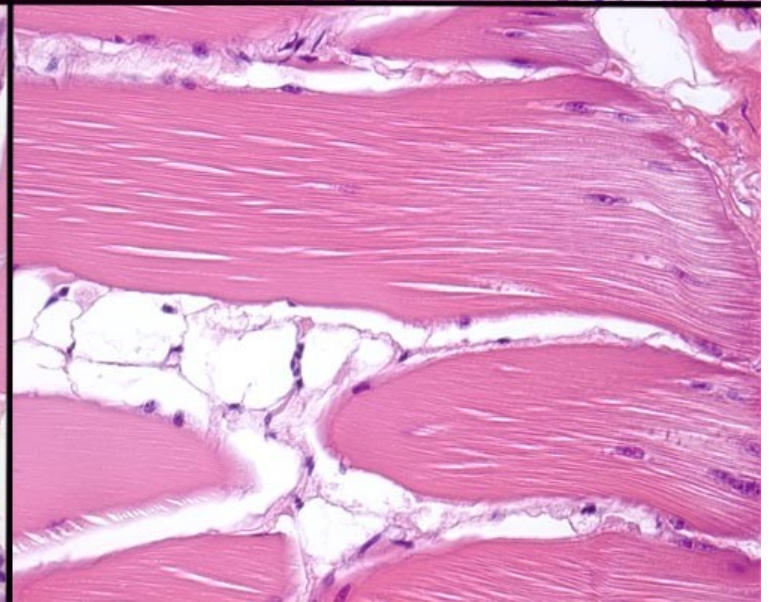
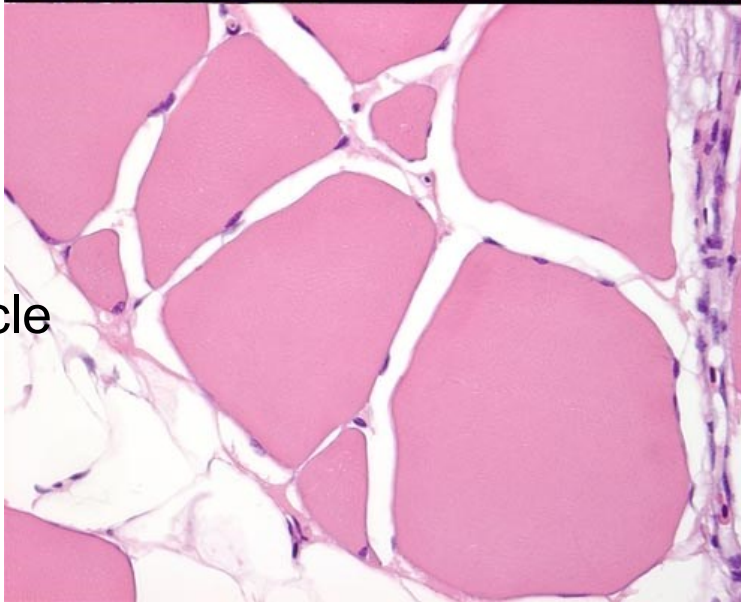
Cross section

Longitudinal section

Red muscle



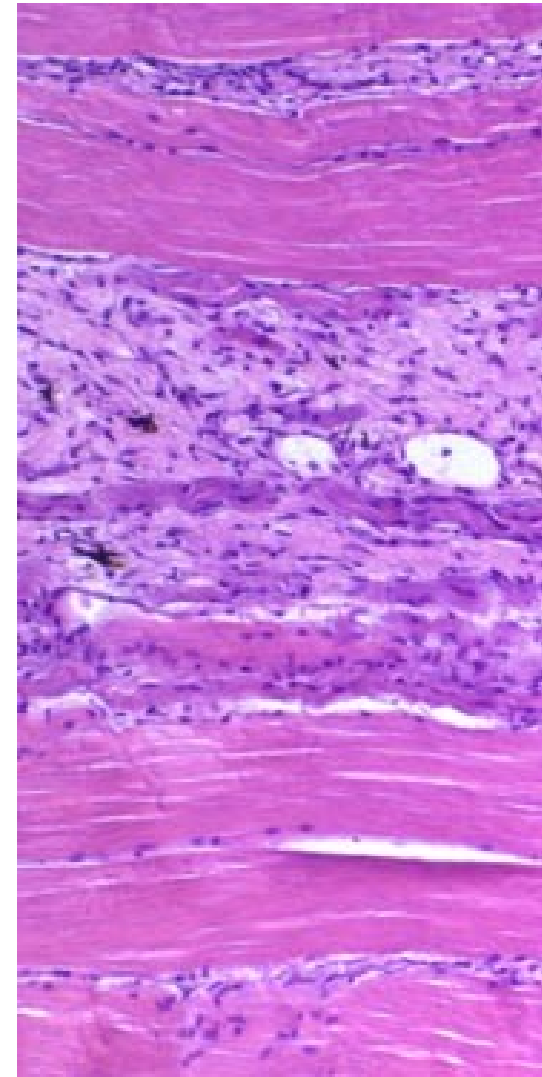
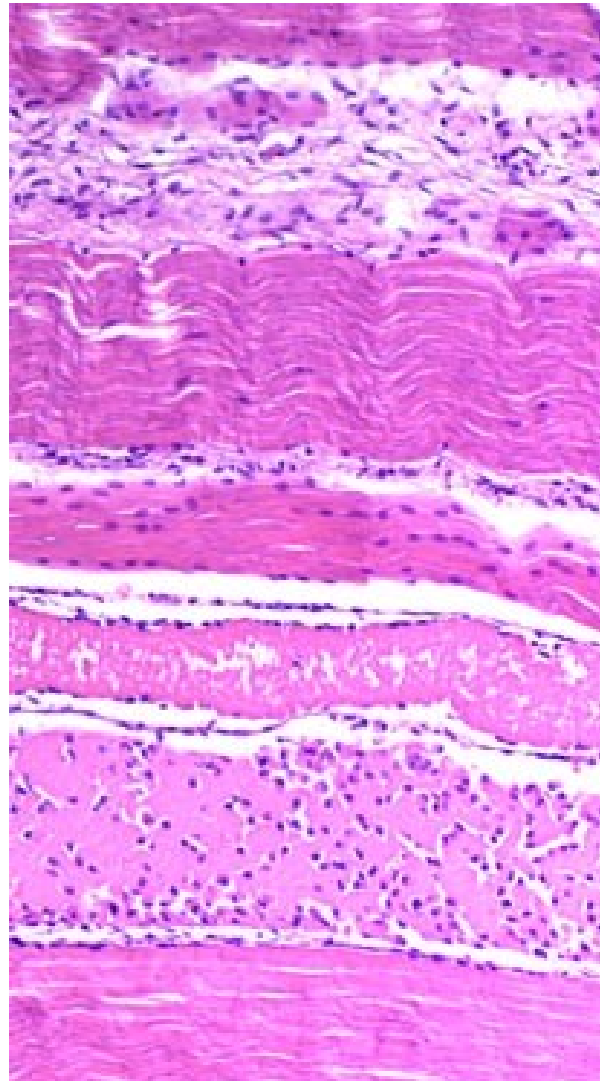
White muscle



## Farm with high prevalence and extensive changes

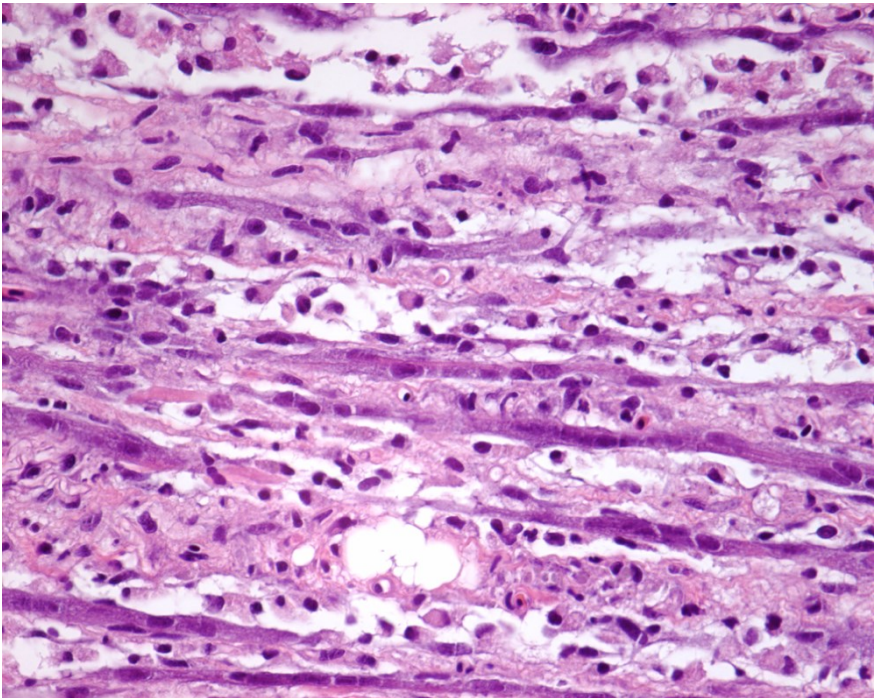
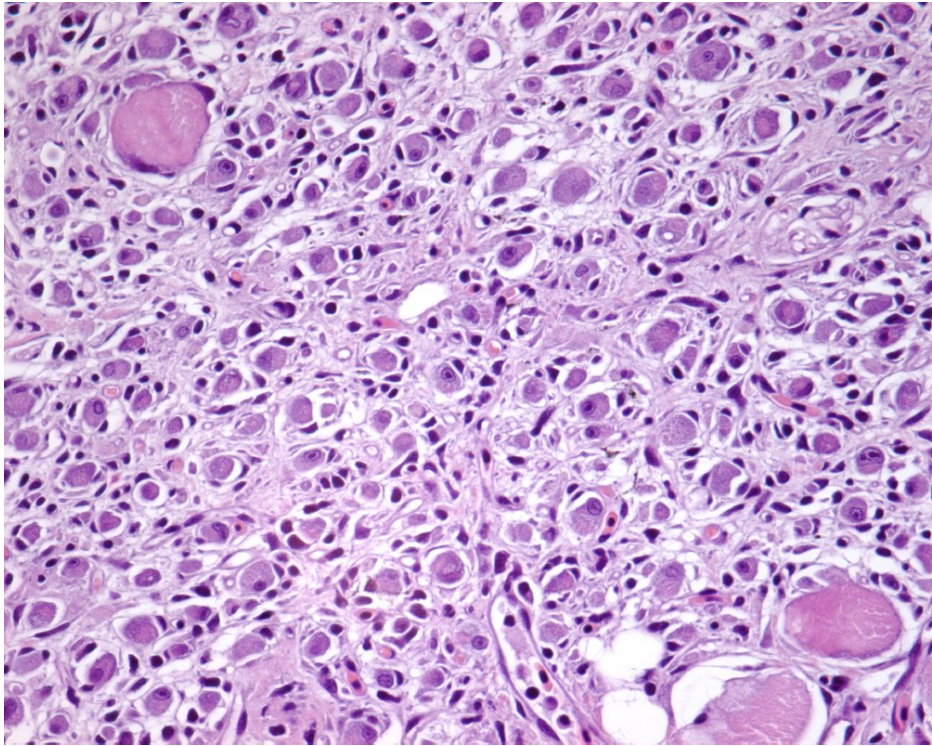
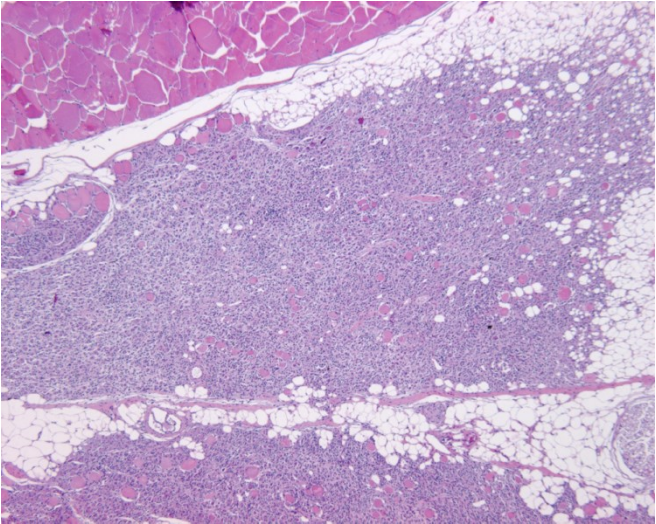


Photo: Local Fish Health Service





# Pancreas disease



# Aetiology?

- **Multifactorial**
  - **Alternatives:**
  - **Nutritional**
  - **Toxicity**
  - **Infectious**
  - **Immune-mediated**


# Quantitative genetics of vaccine-induced side effects in Atlantic salmon

Bjarne Gjerde

Tale Marie Drangsholt, Jørgen Ødegård, Hans B. Bentsen,  
Frode Fridell, Øystein Evensen



PHARMAQ

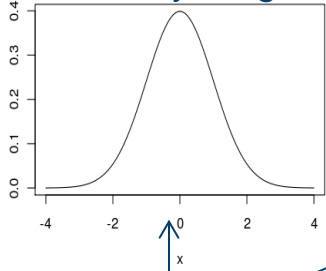
Salmo  Breed  
- when it comes to robustness

 Nofima

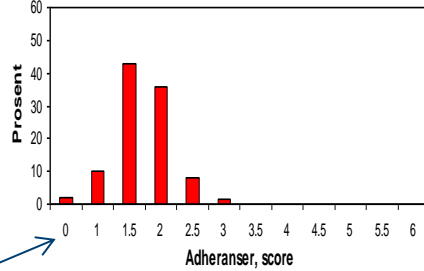
# Quantitative genetics

The study of the effects a large number of unknown genes and unknown environment factors have on phenotypic variation of traits

Body weight

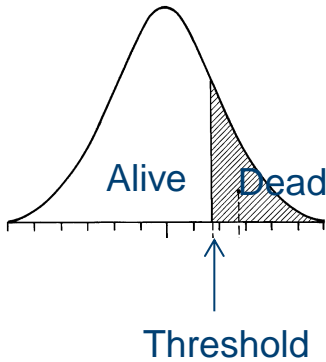


Adhesions, score



$$\text{Phenotype (P)} = \text{Genotype (G)} + \text{Environment (E)}$$

Survival



Sire + Dam + Mendelian sampling

$$\frac{1}{2} V_G$$

$$\frac{1}{2} V_G$$

$$V_P = V_G + V_E$$

$$\text{Heritability, } h^2 = V_G / V_P$$

# Background

- **Vaccination**
  - Negative side effects (adhesions, melanin, reduced growth)
- **Adhesions and melanin deposits heritable traits?**
  - and thus be reduced through selective breeding
- **Magnitude of genetic correlations between traits** presently selected for (e.g. growth, disease resistance) and adhesions and/or melanin deposits?

# Genetic correlation, $r_G$

Adhesions, score


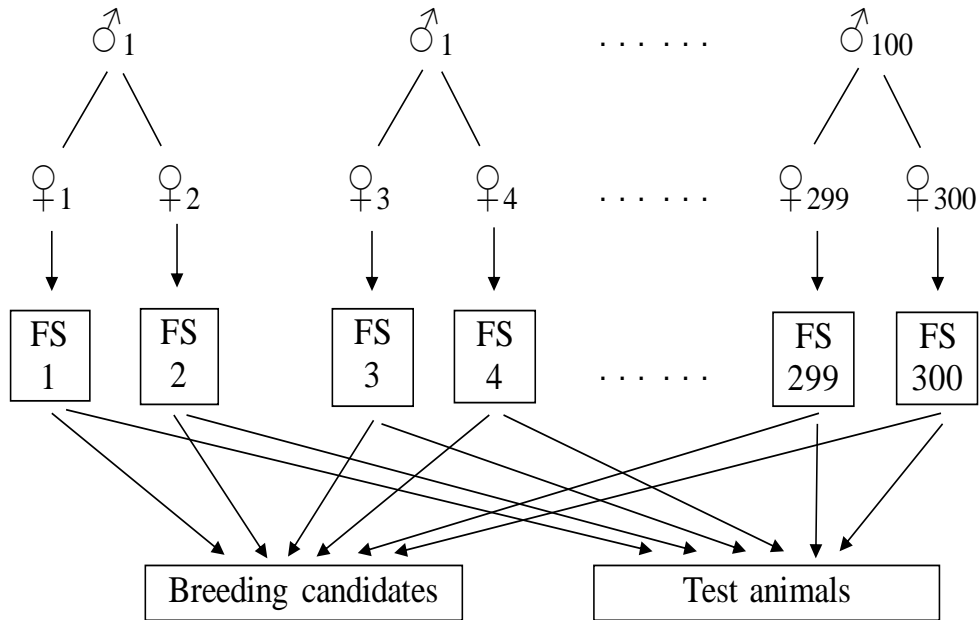
$$P_1 = G_1 + E_1$$

$r_G$

To what degree individuals / families rank similar / different with respect to the true genetic (breeding) value of two trait

Melanin, score

$$P_2 = G_2 + E_2$$



# YC 2007 from SalmoBreed

## 150 families from SalmoBreed

15 fish/family/experimental group

## Vaccine

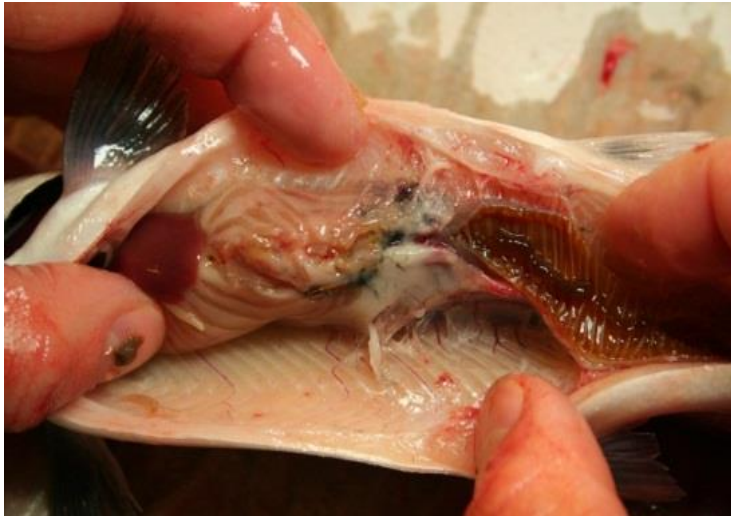- Standard 6-comp. (SV), 0.1 ml/fish
- Experimental 6-comp. (EV), 0.05ml/fish
- Unvaccinated control, saline water (Co)

## Vaccine induced side effects

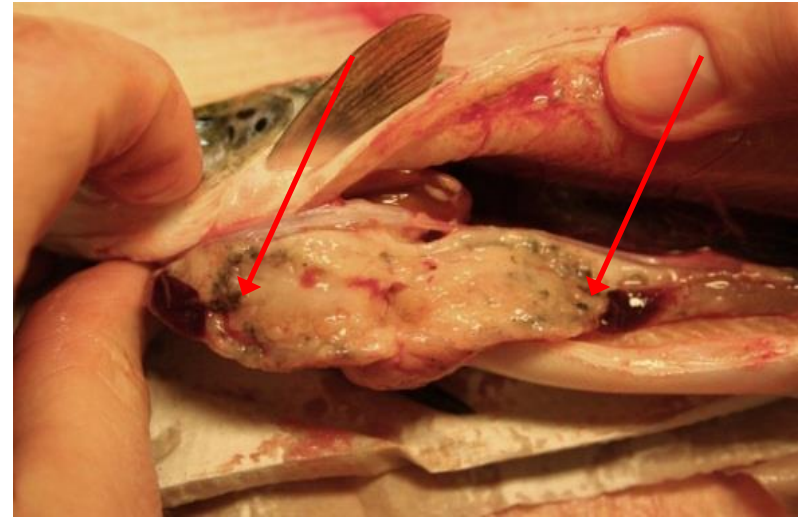
- “Fresh Water” (**FW**)
  - recorded after 3 months at 17 °C at Nofima, Sunndalsøra
- “Sea Water”
  - recorded after 6 (**SW6**) and 12 (**SW12**) months in a net cage in the sea at Nofima, Averøy



# Recordings of vaccine induced side effects



**Adhesions**



**Melanin deposits**


Scored by trained persons from PHARMAQ

**Adhesions:** scale 0-6

- in three regions of the abdominal cavity

**Melanin deposits:** scale 0-3

- internal organs and abdominal wall



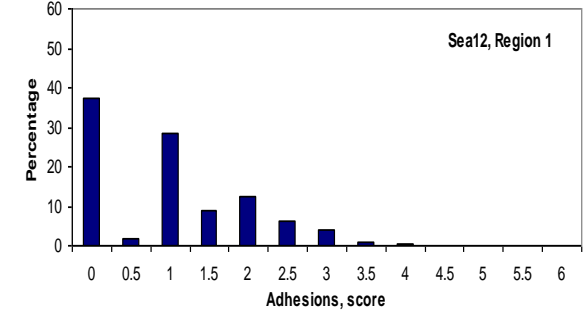
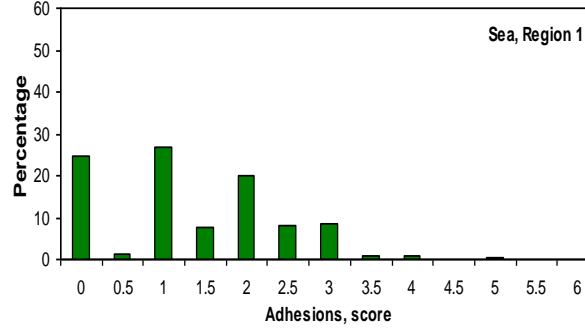
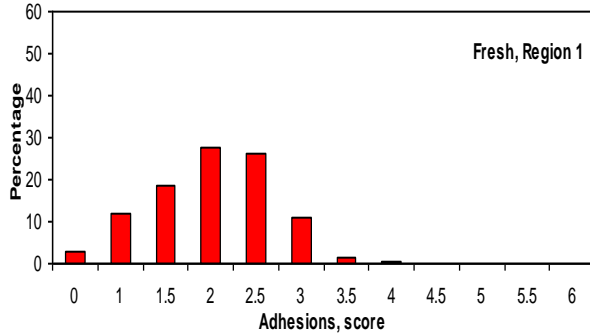
# Adhesions – in different regions of abdominal cavity

Region 1

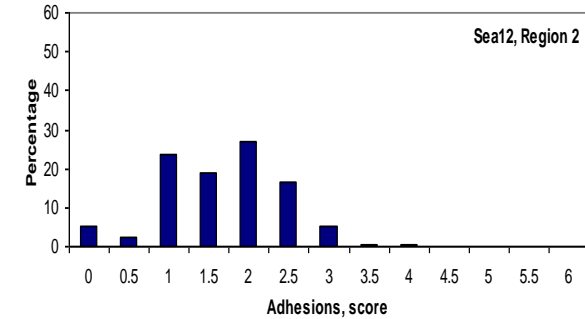
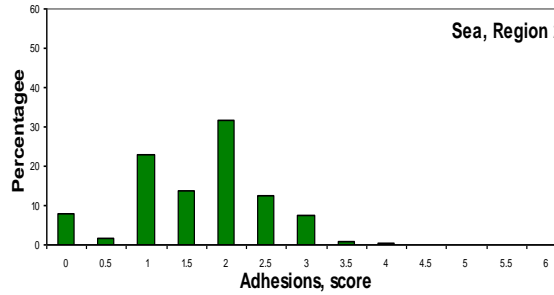
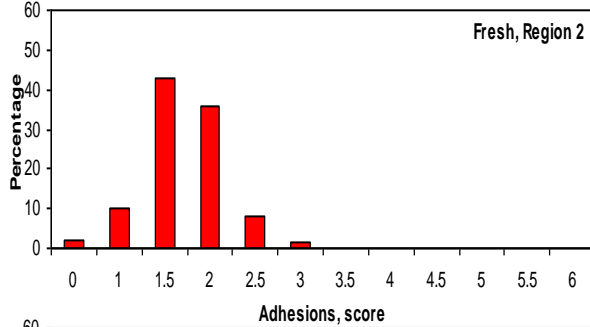
FW

SW6

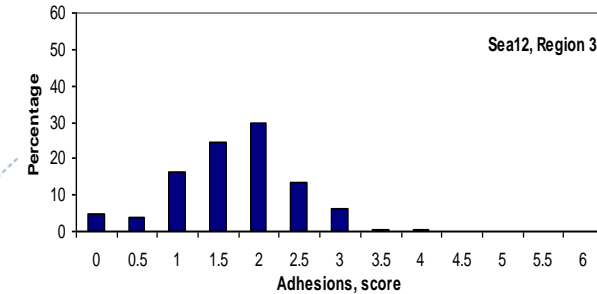
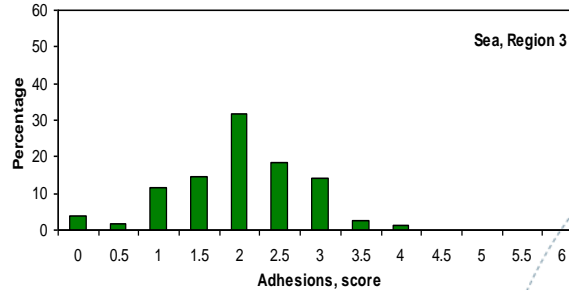
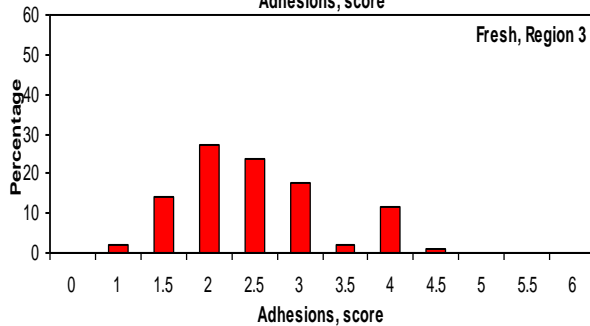
SW12



Region 2



Region 3



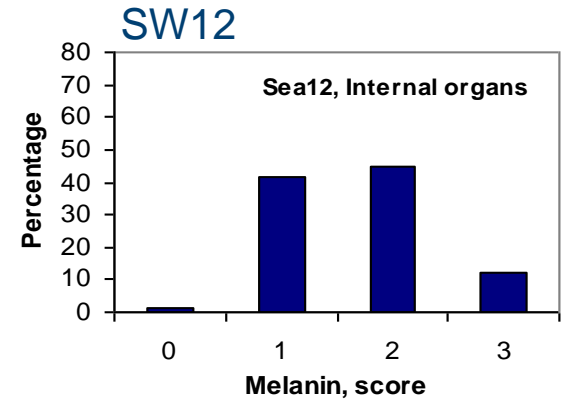
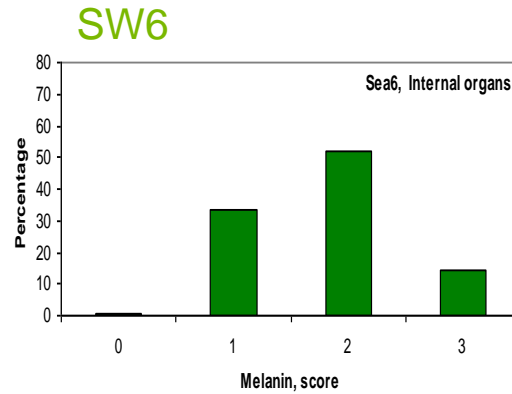
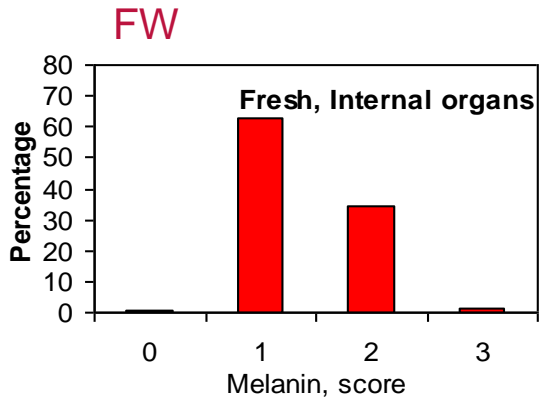
$\bar{X}=2.06$ ;  $SD=0.49$

$\bar{X}=1.68$ ;  $SD=0.65$

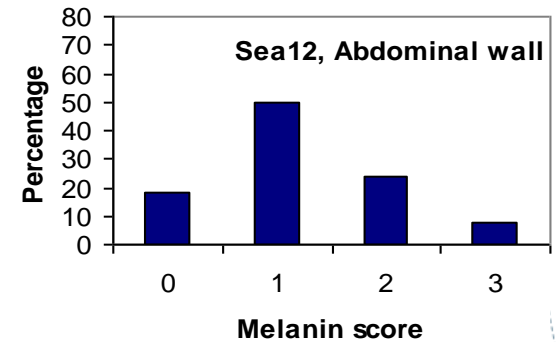
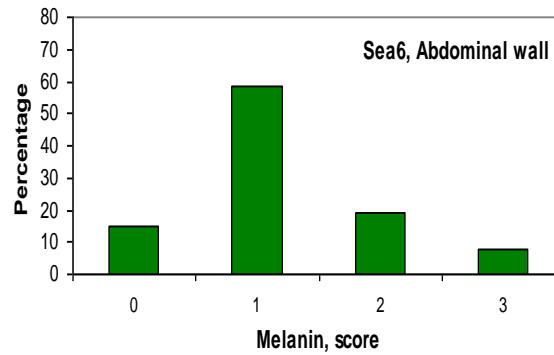
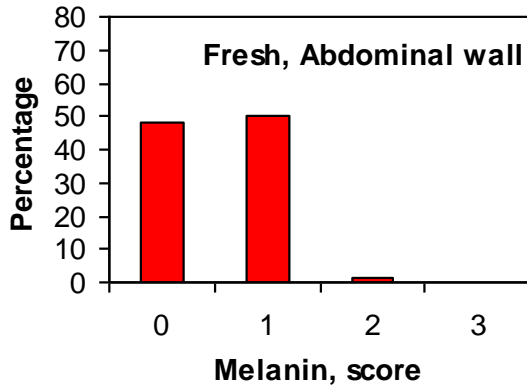
$\bar{X}=1.46$ ;  $SD=0.56$

# Melanin score - intern organs and abdominal wall

Internal organs



Abdominal wall



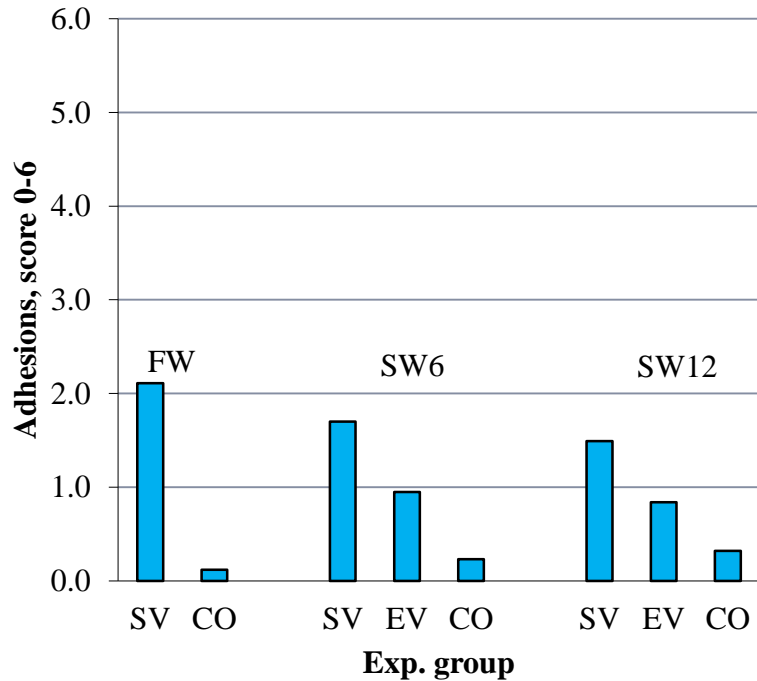
$\bar{X}=0.95$ ;  $SD=0.44$

$\bar{X}=1.49$ ;  $SD=0.62$

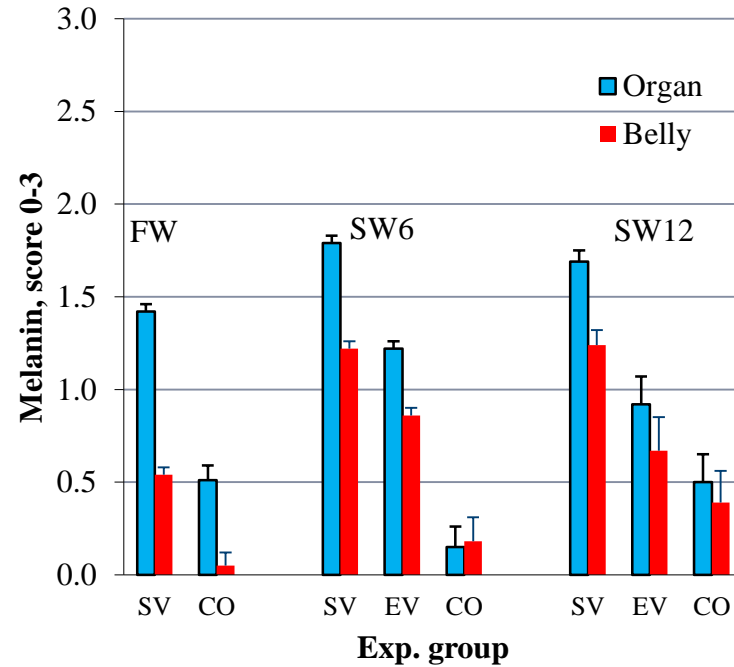
$\bar{X}=1.45$ ;  $SD=0.69$

# Effects of different Vaccines

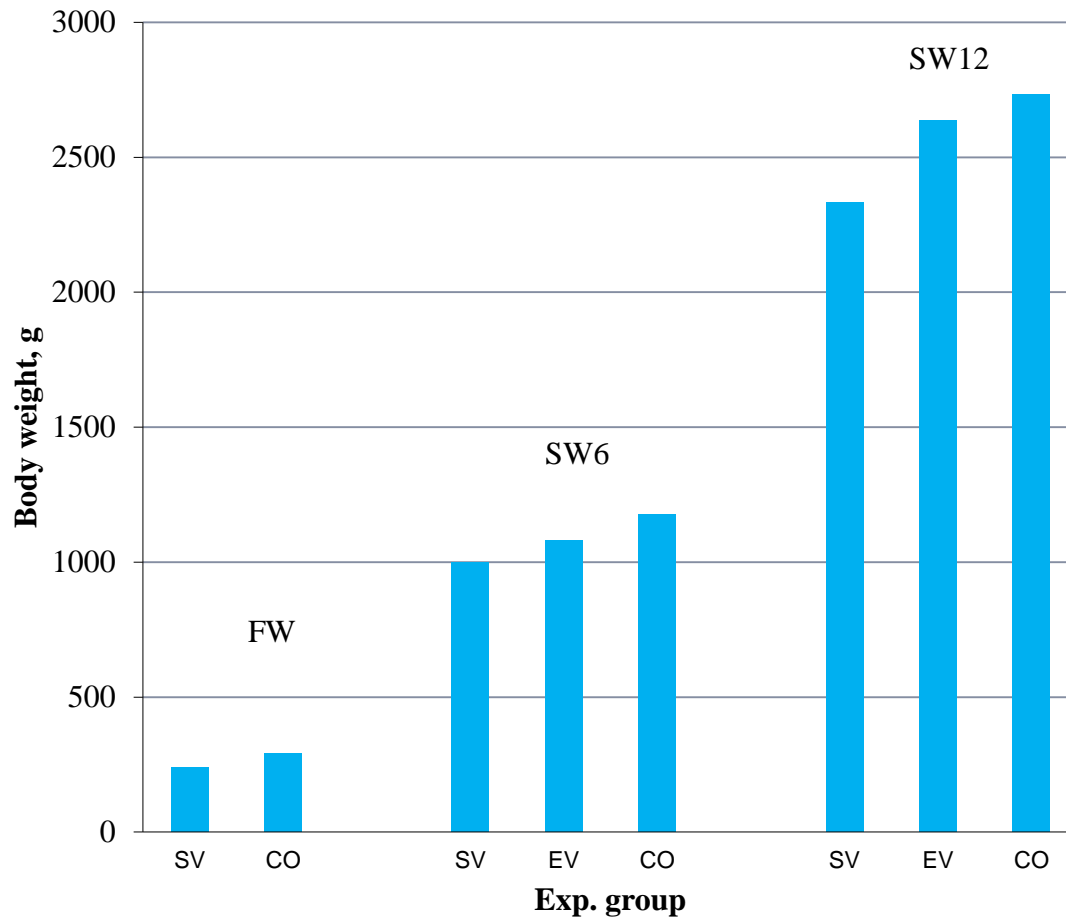
## Adhesions, score 0-6



## Melanin, score 0-3



# Growth



# Heritabilities and genetic correlations

Exp. group	Heritability		Genetic corr.
	Adhesions	Melanin	Adh - Mel
FW	0.31 ±0.05	0.27 ±0.05	0.52 ±0.11
SW6-SV	0.19 ±0.04	0.28 ±0.05	0.89 ±0.06
SW12-SV	0.16 ±0.04	0.30 ±0.05	0.87 ±0.06
SW6-EV	0.08 ±0.03	0.11 ±0.03	0.76 ±0.14

# Genetic correlations between exp. groups

---

	<b>Adhesions</b>	<b>Melanin</b>
<b>FW vs. SW12</b>	0.48 ± 0.14	0.61 ± 0.11
<b>SW6 vs. SW12</b>	0.92 ± 0.11	0.89 ± 0.07

# Conclusions

- Adhesions and Melanin deposits are heritable traits,
  - can thus be reduced through selective breeding
- Highly genetic correlated traits in the seawater period
  - thus to a large extent caused by the same genes
- Substantial re-ranking of families for these traits in freshwater and seawater – test of families for these traits should be performed based on data recorded in seawater
- Vaccine induced side effects can be reduced through the development of improved vaccines
  - thus leaving higher scope for genetic gain for other traits



# Genetic correlations between resistance to furunculosis and vaccine induced side effects

---

	Adhesions	Melanin
<b>Resist, to fur. vaccinated fish</b>	0.06 ± 0.16	0.03 ± 0.15
<b>Resist. to fur. unvaccinated fish</b>	0.24 ± 0.16	0.00 ± 0.15
<b>Growth, SW12</b>	0.08 ± 0.15	-0.04 ± 0.14

---

All correlations not significantly different from zero

# Conclusions

Selection for increased resistance to furunculosis or increased growth is not expected to give any positive or negative correlated responses in vaccine induced side effects

This indicates that adhesions and melanin deposits are caused by other components of the immune system than those responsible for the genetic variation in both innate and acquired resistance to furunculosis

# For more details see:

Heredity (2011), 1-7  
© 2011 Macmillan Publishers Limited All rights reserved 0018-067X/11  
www.nature.com/hdy

## ORIGINAL ARTICLE

### Quantitative genetics of disease resistance in vaccinated and unvaccinated Atlantic salmon (*Salmo salar* L.)

TMK Drangsholt<sup>1,2</sup>, B Gjerde<sup>1,2</sup>, J Ødegård<sup>1,2</sup>, F Finne-Fridell<sup>3</sup>, Ø Evensen<sup>4</sup> and HB Bentsen<sup>2</sup>  
<sup>1</sup>Department of Animal and Aquacultural Sciences, Norwegian University of Life Sciences (UMB), Ås, Norway; <sup>2</sup>Nofima Marin, Ås, Norway; <sup>3</sup>PHARMAQ AS, Oslo, Norway and <sup>4</sup>Norwegian School of Veterinary Science, Oslo, Norway

Aquaculture 324-325 (2012) 312-314



Short communication

### Genetic correlations between disease resistance, vaccine-induced side effects and harvest body weight in Atlantic salmon (*Salmo salar*)

Tale Marie Karlsson Drangsholt<sup>a,b,\*</sup>, Bjarne Gjerde<sup>a,b</sup>, Jørgen Ødegård<sup>a,b</sup>, Frode Finne-Fridell<sup>c</sup>, Øystein Evensen<sup>d</sup>, Hans Bernhard Bentsen<sup>a</sup>

<sup>a</sup> Nofima, PO Box 5010, 1432 Ås, Norway

<sup>b</sup> Norwegian University of Life Sciences (UMB), Dept. of Animal and Aquacultural Sciences, PO Box 5003, 1432 Ås, Norway

<sup>c</sup> PHARMAQ AS, PO Box 267 Skøyen, 0213 Oslo, Norway

<sup>d</sup> Norwegian School of Veterinary Science, PO Box 8146 Dep, 0033 Oslo, Norway

Aquaculture 318 (2011) 316-324



Contents lists available at ScienceDirect

Aquaculture

journal homepage: [www.elsevier.com/locate/aqua-online](http://www.elsevier.com/locate/aqua-online)



### Quantitative genetics of vaccine-induced side effects in farmed Atlantic salmon (*Salmo salar*)

Tale Marie K. Drangsholt<sup>a,b,\*</sup>, Bjarne Gjerde<sup>a,b</sup>, J. Ødegård<sup>a,b</sup>, F. Fridell<sup>c</sup>, Hans B. Bentsen<sup>b</sup>

<sup>a</sup> Norwegian University of Life Sciences (UMB), PO Box 5003, 1432 Ås, Norway

<sup>b</sup> Nofima, PO Box 5010, 1432 Ås, Norway

<sup>c</sup> PHARMAQ AS, PO Box 267 Skøyen, 0213 Oslo, Norway

Aquaculture 287 (2009) 52-58



### Genetic (co)variation of vaccine injuries and innate resistance to furunculosis (*Aeromonas salmonicida*) and infectious salmon anaemia (ISA) in Atlantic salmon (*Salmo salar*)

Bjarne Gjerde<sup>a,\*</sup>, Øystein Evensen<sup>b</sup>, Hans B. Bentsen<sup>a</sup>, Arne Storset<sup>c</sup>

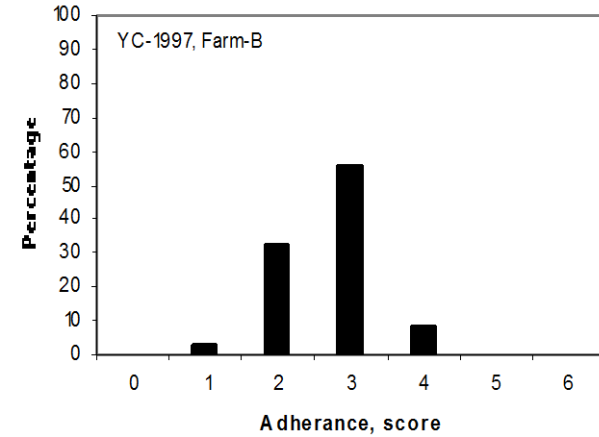
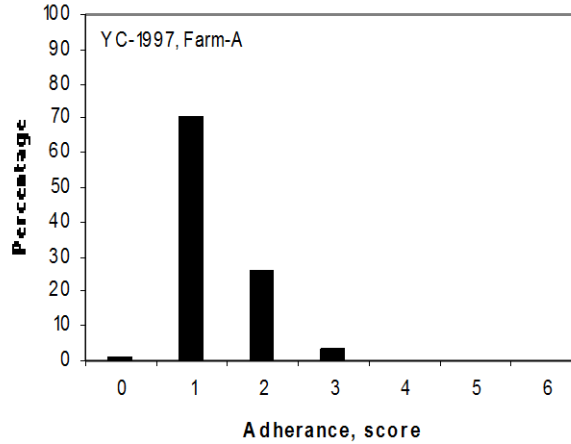
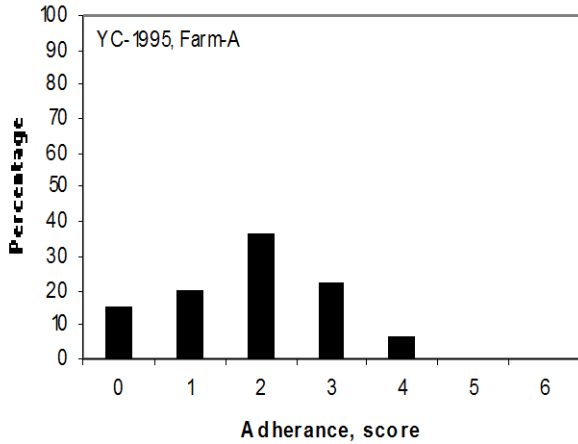
<sup>a</sup> Nofima Marine, P.O. Box 5010, N-1432 Ås, Norway

<sup>b</sup> Norwegian School of Veterinary Science, Department of Basic Sciences and Aquatic Medicine, P.O. Box 8146 Dep Oslo 0033, Norway

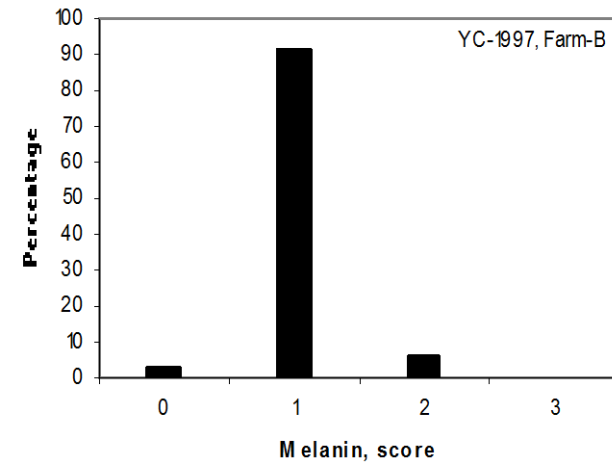
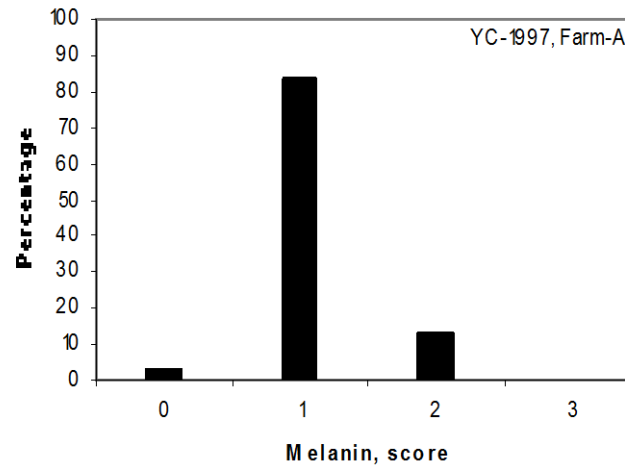
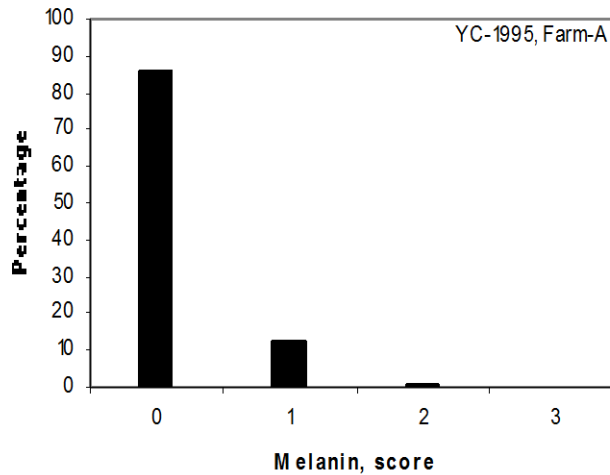
<sup>c</sup> Aqua Gen AS, P.O. Box 1240, Pir-Senteret, N-7462 Trondheim, Norway

# YC 1995 and 1997 from AquaGen

## Adhesions

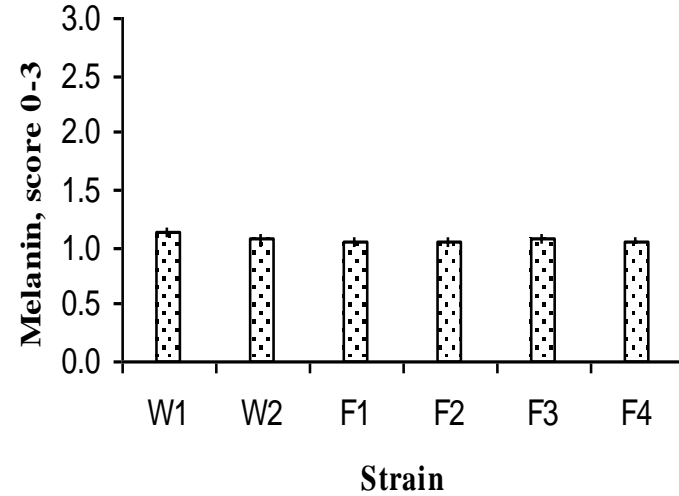
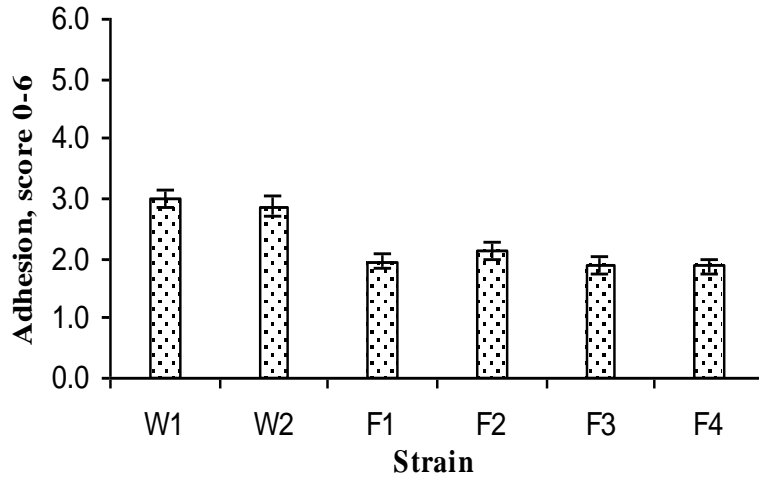


## Melanin



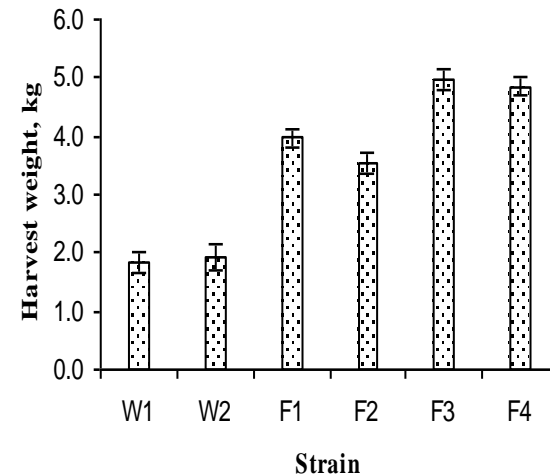
# AquaGen YC 1995 and 1997

Gjerde, B., Evensen, Ø., Bentsen, H.B., Storset, A. 2009. *Aquaculture* 287, 52-58.

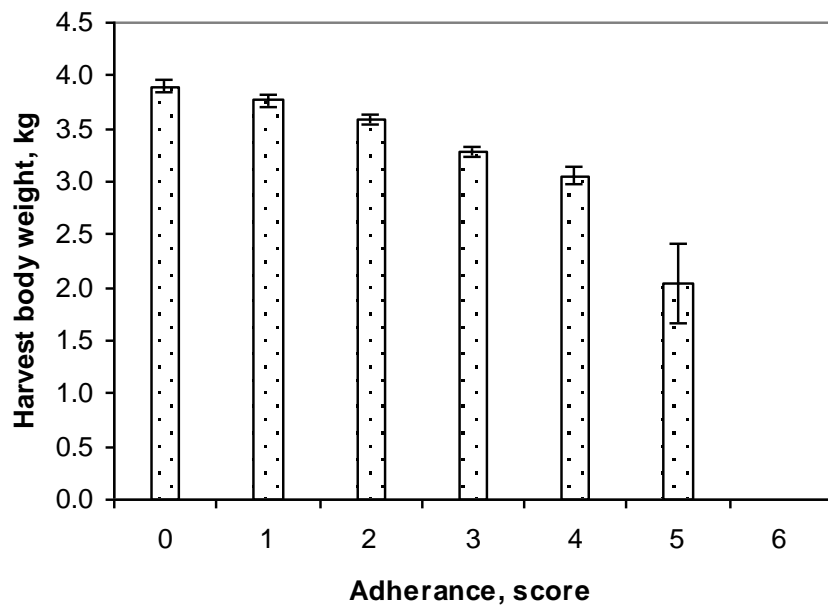


	$h^2 \pm se$
Adhesion, score	$0.19 \pm 0.03$
Melanin, score	$0.19 \pm 0.03$

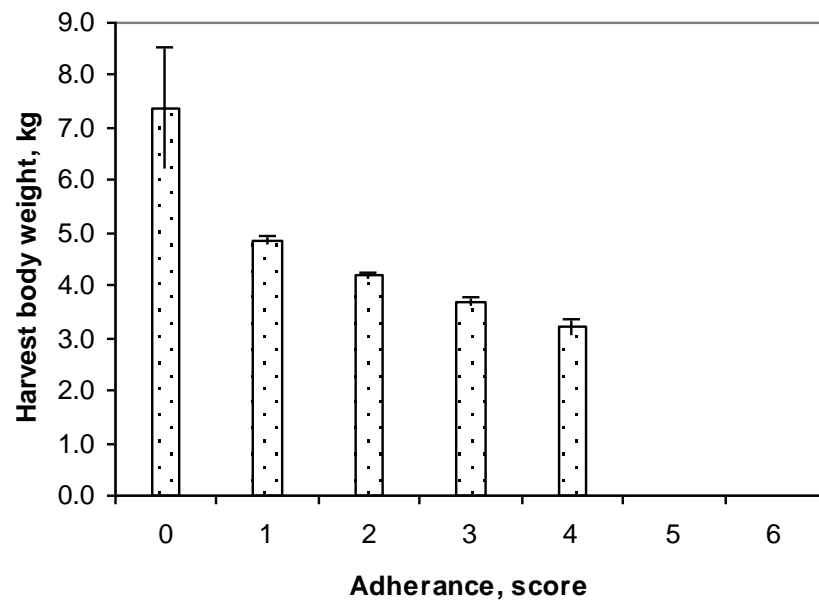
	Weight	Adhesion	Melanin
Harvest weight	-	$-0.43 \pm 0.11$	$-0.21 \pm 0.12$
Adhesions, score	$-0.26 \pm 0.02$	-	$0.74 \pm 0.08$
Melanin, score	$-0.17 \pm 0.02$	$0.38 \pm 0.02$	-



**YC-1995**



**YC-1997**



# Dark spots in salmon fillets

## statistics and status on causalities

Turid Mørkøre

Nofima

DARK SPOTS IN SALMON FILLETS  
Workshop , BEST WESTERN Oslo Airport Hotel  
November 5<sup>th</sup> 2013

A top-down view of a white ceramic bowl filled with numerous pieces of fresh, raw salmon fillets. The salmon is cut into irregular, bite-sized chunks, showing its characteristic orange-pink color and white marbling. The bowl is set against a plain white background.

**Common goal**

---

**Sustainable and cost  
efficient production of  
high-quality food**

**We are all involved in food production**



# Starting point - 2009

- **Dark stained fillets are a costly problem for the aquaculture industry**
- **Dark spots are due to melanin deposition**
- **The cause is related to vaccine / vaccination**
- **Statistics missing**

# FHF project on quality deviations – conclusion 2012

- Dark spots due to different causes  
– NOT ONLY VACCINATION
- The impact of vaccine/vaccine regime is,  
however, still relevant to study



Veterinærinstituttet  
National Veterinary Institute



# Mørke flekker i laksefilet 2012-2015

-Årsaker til forekomst og forebyggende tiltak



## Prosjektbeskrivelse

### Sammendrag:

Det overordnede målet er å forhindre dannelse av mørke flekker i laksefilet. I dette ligger en søken etter årsaker til at flekkene oppstår for at kunne anbefale tiltak som kan bidra til å løse problemet. Aktivitetene i prosjektet er delt i fire arbeidspakker (AP): <sup>1</sup>Kartlegging, <sup>2</sup>Vaksine og helse, <sup>3</sup>Fôr og <sup>4</sup>Sortering og skade. Det vil være et nært samarbeid mellom AP1-4, som vil gå parallelt i perioden 2012 og ut 2014.

### Går til:

Fiskeri og havbruksnæringens forskningsfond

Rutinemessig kartlegging av forekomst av mørke filetflekker utføres av kvalitetskontrollører ved filetanlegg med geografisk spredning. Registreringene danner grunnlag for etterrettelig statistikk samt dybdeanalyse for å avdekke årsakssammenhenger. To basispopulasjoner med PIT-tag merket uvaksinert og vaksinert (ulike regimer) laks produseres: nullårsmolt (BP0+) og ettårsmolt (BP1+). Etter vaksineringsundersøkes laksen jevnlig for mørke filetpigmenter frem til slakt. Produksjonsparametere, morfometri og blod analyses også. Mørke filetflekker undersøkes ved avbildende spektroskopi, foto, histologi, sammensetning og genuttrykk. Øvrige kvalitetsegenskaper undersøkes av utvalgt fisk. BP0+ vil i en 3 måneders periode for slakt få et slutfôr med og uten forhøyet sink, vitamin E eller fôrtoksiner (ulike vaksinereregimer blandet i merder). BP1+ vil undersøkes mht effekt av lavt sinknivå frem til vaksinerings samt fra sjøutsett til slakt. I



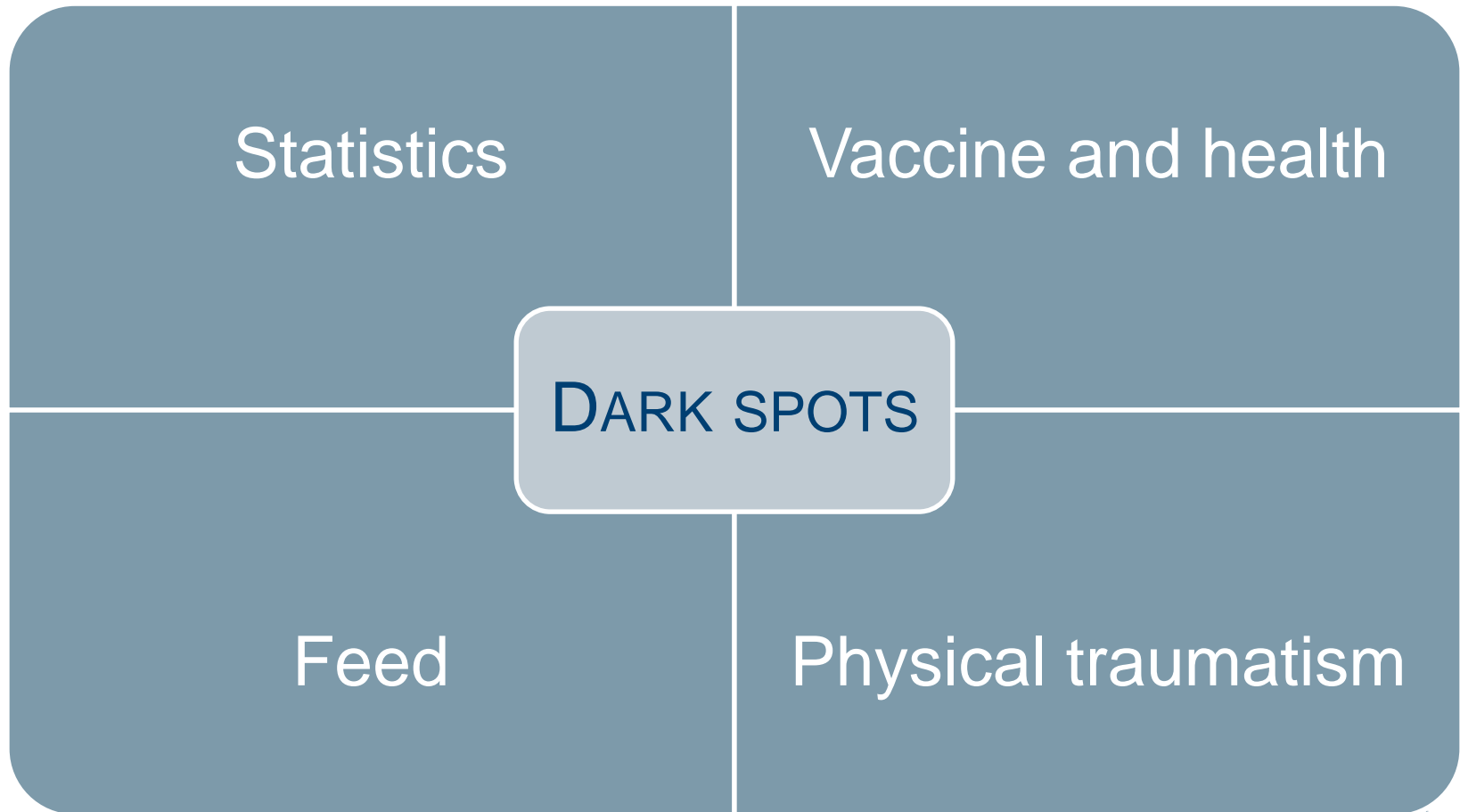
"DARK SPOTS IN SALMON FILLETS"

Workshop , BEST WESTERN Oslo Airport Hotel

November 5<sup>th</sup> 2013



# Project topics



# Parameters being studied in the project

Reliable and updated statistics

Genetic background  
Environment conditions  
Vaccination  
Health status / disease  
Farming conditions


Organisation of the project  
→ obtain broad information  
→ Define causes

Dietary composition

Slaughter procedure / stress

# Registrations

MELANIN I FILET (poeng)				
Ingen misfarging	0	Flekk 3 - 6cm	4	
Diffus flekk, alle størrelser	1	Område større enn 6cm	8	
Flekk mindre enn 3cm	2	Gjennomsnitt	0.00	



Skjema sendes til [thomas.larsson@nofima.no](mailto:thomas.larsson@nofima.no)

FLEKKER I FILET (poeng)					Frivillige registreringer	
flere flekker i samme område summeres					Utført:	JA
Filet	Total poeng	Buk 1	Buk 2	Rygg	Blek, 0/1 (se fanen "Forklaring")	Gaping, 0/1 (se fanen "Forklaring")
1	0	0	0	0	0	0
2	0	0	0	0	0	0
3	0	0	0	0	0	0
4	0	0	0	0	0	0
5	0	0	0	0	0	0
6	0	0	0	0	0	0
7	0	0	0	0	0	0
8	0	0	0	0	0	0
9	0	0	0	0	0	0
10	0	0	0	0	0	0
11	0	0	0	0	0	0
12	0	0	0	0	0	0
13	0	0	0	0	0	0
14	0	0	0	0	0	0
15	0	0	0	0	0	0
16	0	0	0	0	0	0
17	0	0	0	0	0	0
18	0	0	0	0	0	0
19	0	0	0	0	0	0
20	0	0	0	0	0	0
21	0	0	0	0	0	0
22	0	0	0	0	0	0
23	0	0	0	0	0	0
24	0	0	0	0	0	0
25	0	0	0	0	0	0

Kommentarer

F. eks. om det er fisk med flere flekker innenfor samme område eller avvik for partiet (bløt filet, brus, deformiteter)

SPØRSMÅL SOM BESVARES FOR HVER GRUPPE FISK SOM BEDØMMES

Sett gjerne ? der informasjon mangler

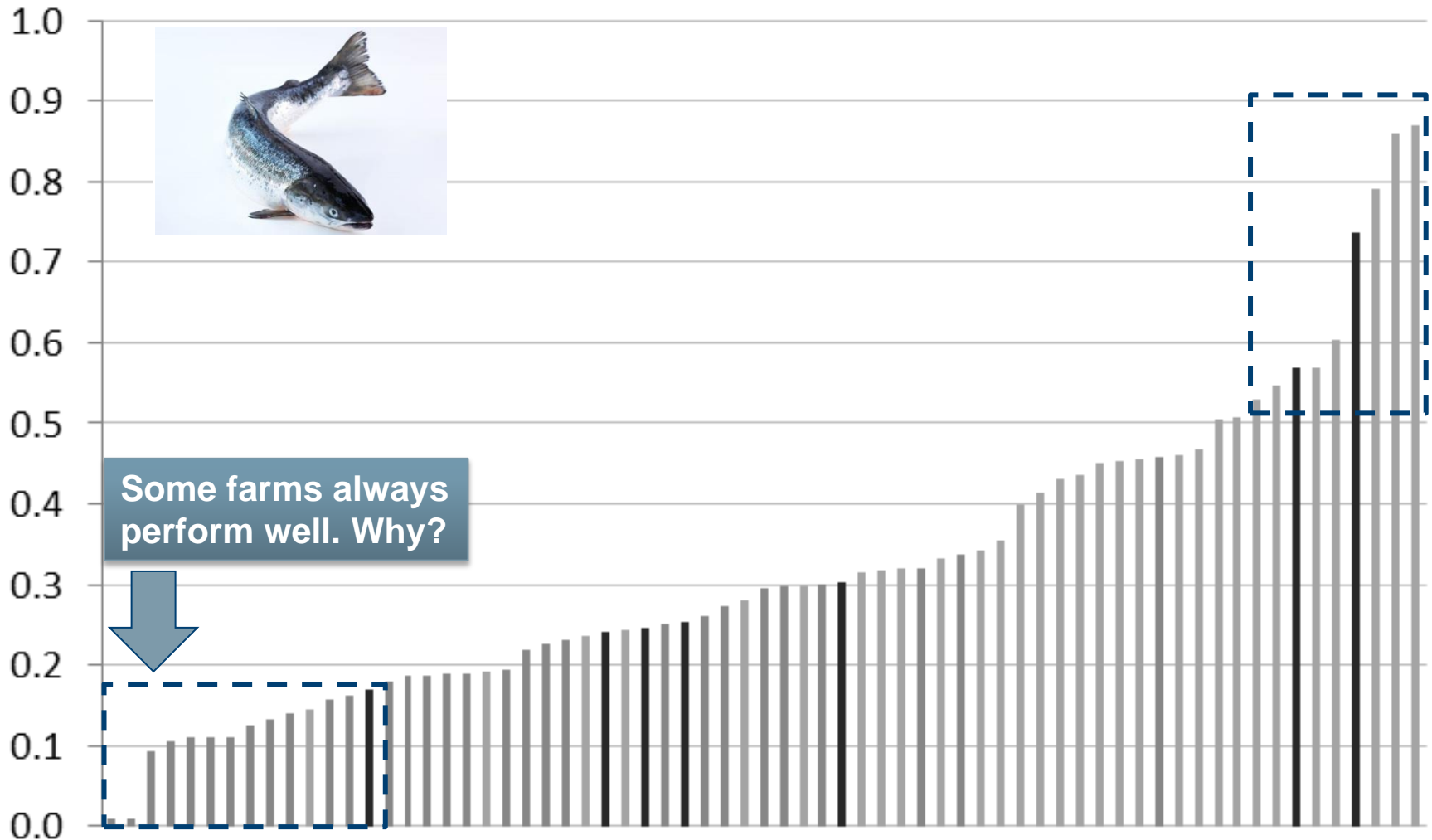
Prosessanlegg navn/nr:			
Navn på bedømmer:			
Lokalitetsnr (navn):			Kvalitetsklasse:
Dato ved slakt:	Sjøtemp:		Superior
Dato ved måling:	Merd nr:		Ordinær
Vektklasse:	Lot nr:		Produksjon

TILLEGGSINFORMASJON

Smolt			
Leverandør:			
Utsett måned:	år:	Stamme:	
Maskinvaksinert: JA		Vaksinetype:	
NEI		Vaksineringstemp:	

# Seawater farms

- Updated June 2013



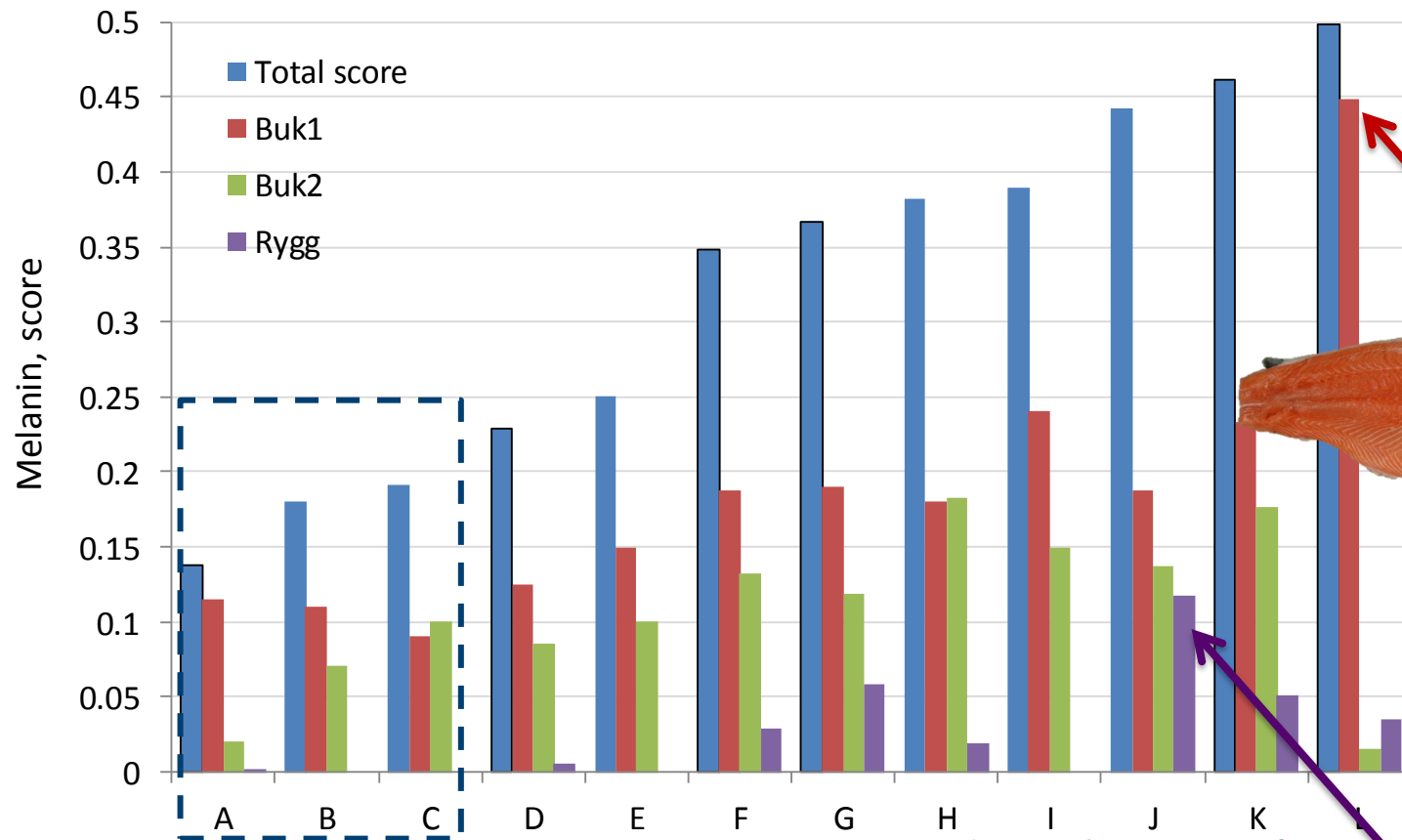
All background data are anonymised

"DARK SPOTS IN SALMON FILLETS"

Workshop , BEST WESTERN Oslo Airport Hotel

November 5<sup>th</sup> 2013

## Smolt producer – Mid-Norway





# Dark spots - Development

	Frequency	Belly flap	Dorsal muscle	Number reg.
<b>2011</b>	<b>13.4%</b>	<b>12.6%</b>	<b>0.8%</b>	<b>35.000</b>
<b>2012</b>	<b>16.1%</b>	<b>15.3%</b>	<b>0.8%</b>	<b>25.000</b>
<b>2013 (- okt)</b>	<b>17.9%</b>	<b>16.1%</b>	<b>1.8%</b>	<b>36.000</b>

Mid- and South:

17-20% (June 2013)

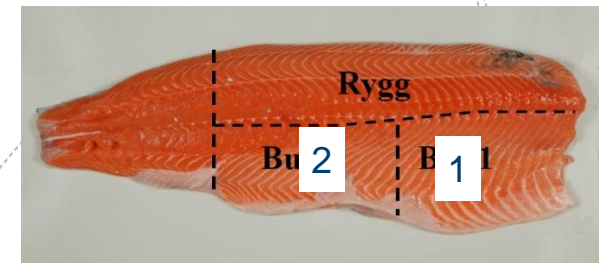
Belly flap 1 + 2

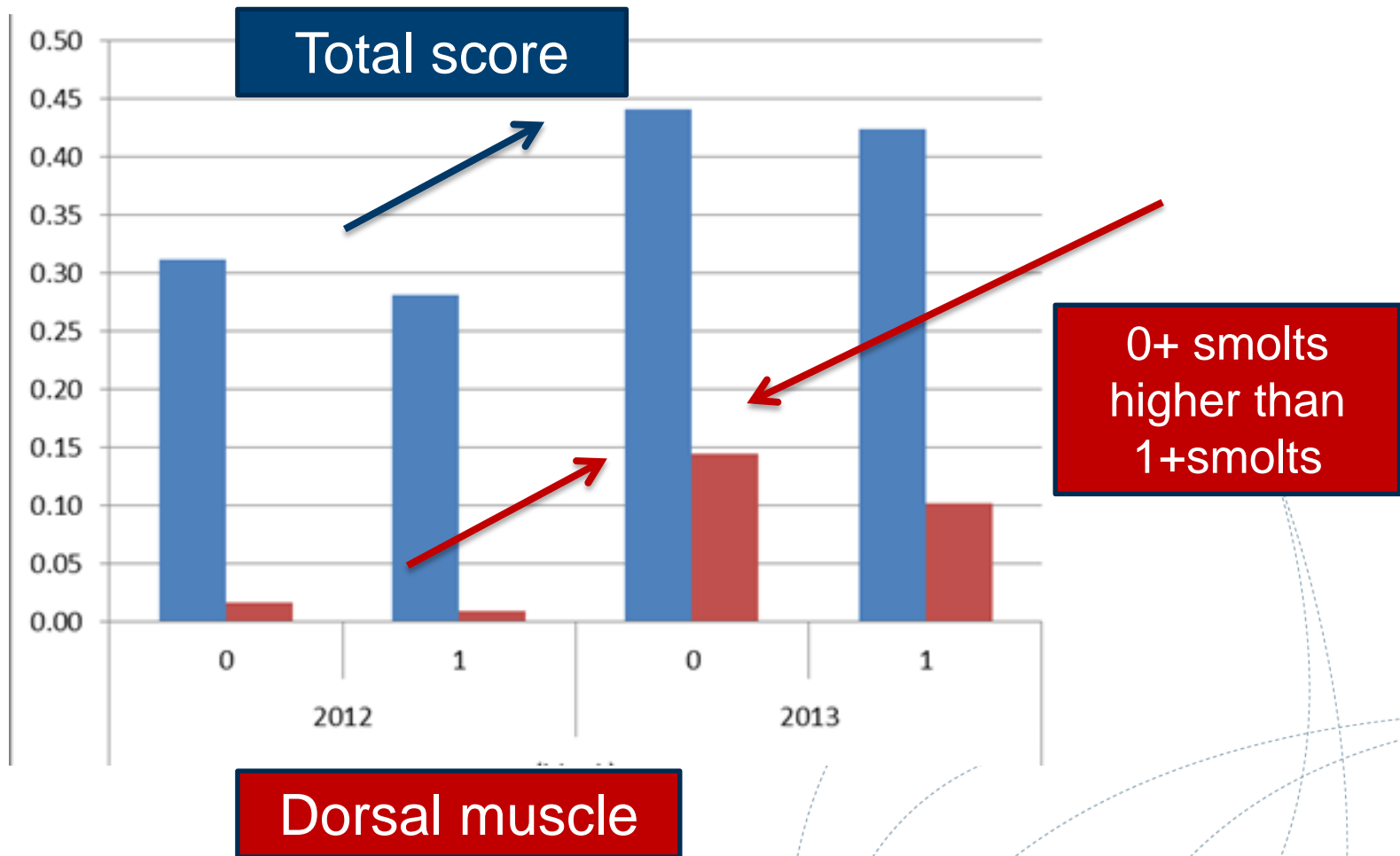
North

13% (June 2013)

Belly flap 1

- but frequency of dark pigmented dorsal muscle increasing in 2013






# Spots

Statistics

More frequent  
in South-Mid Norway




Most frequent  
(70% of all spots)




Causes largest  
problems

# Spots



# Dark spots

May be difficult to distinguish between blood and melanin




«Red spot»



«Black spot»

# Development ?



Blood



Melanin





Scar tissue

**"DARK SPOTS IN SALMON FILLETS"**

Workshop , BEST WESTERN Oslo Airport Hotel

November 5<sup>th</sup> 2013

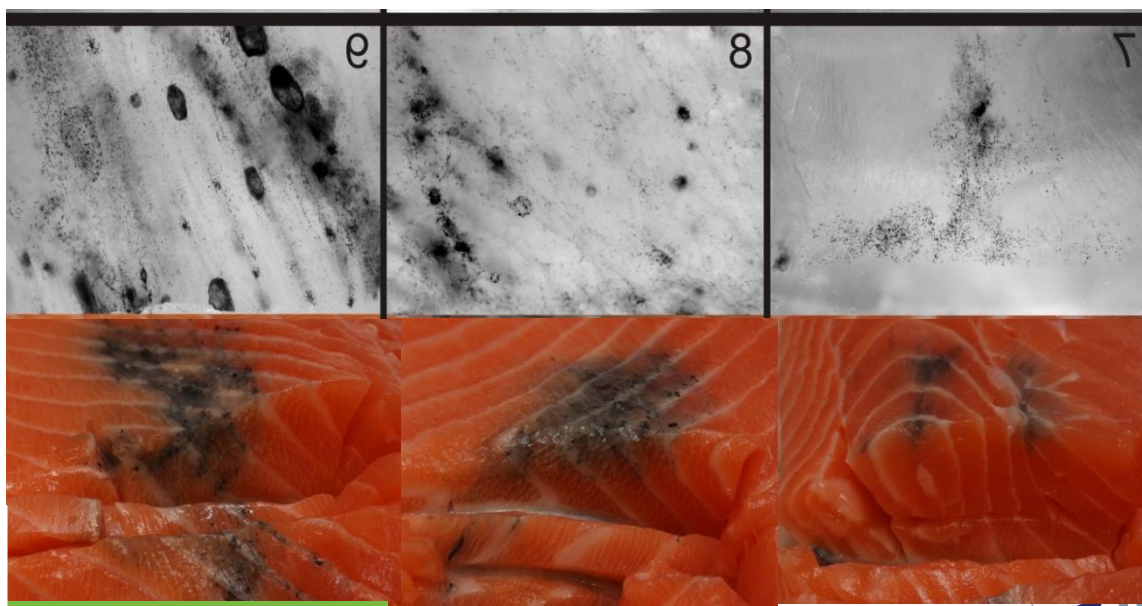
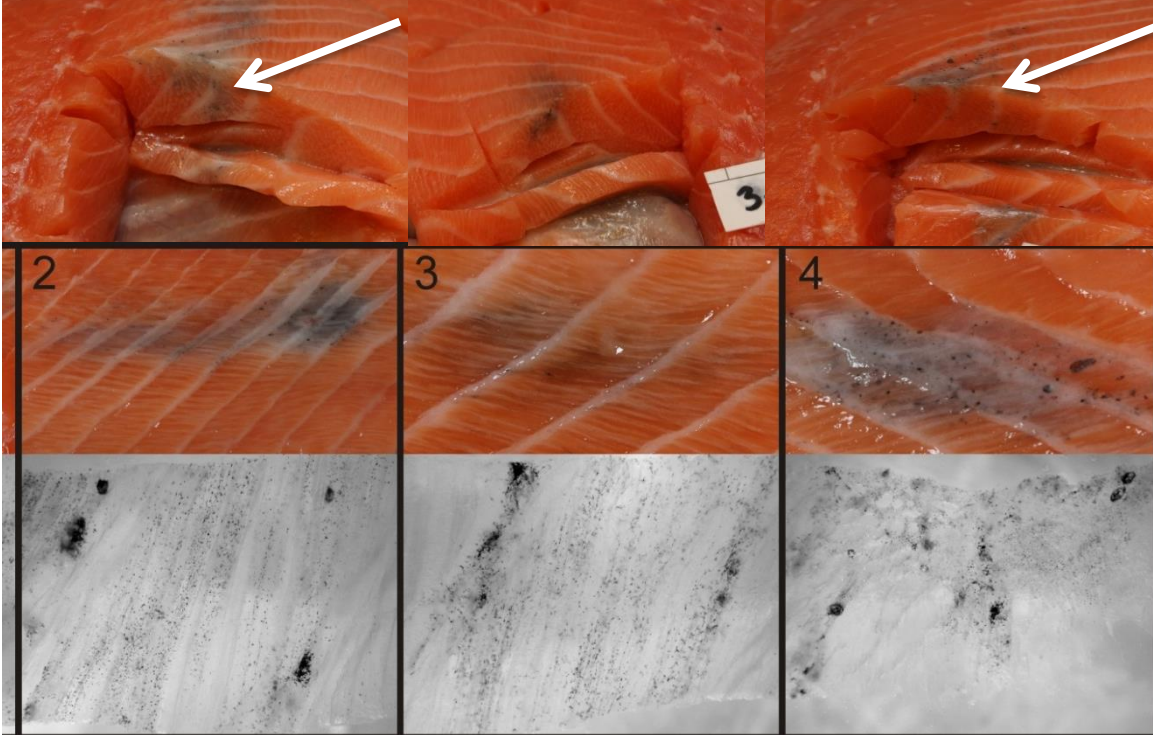


# Magnification

**"DARK SPOTS IN SALMON FILLETS"**

Workshop , BEST WESTERN Oslo Airport Hotel

November 5<sup>th</sup> 2013



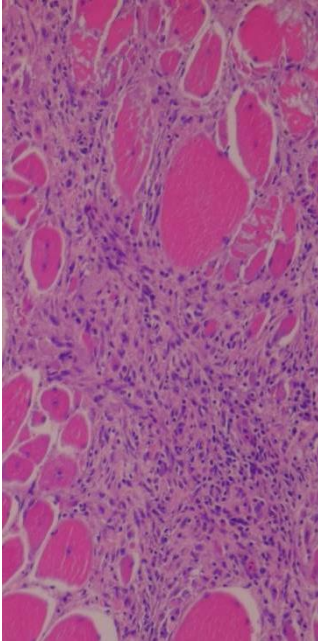
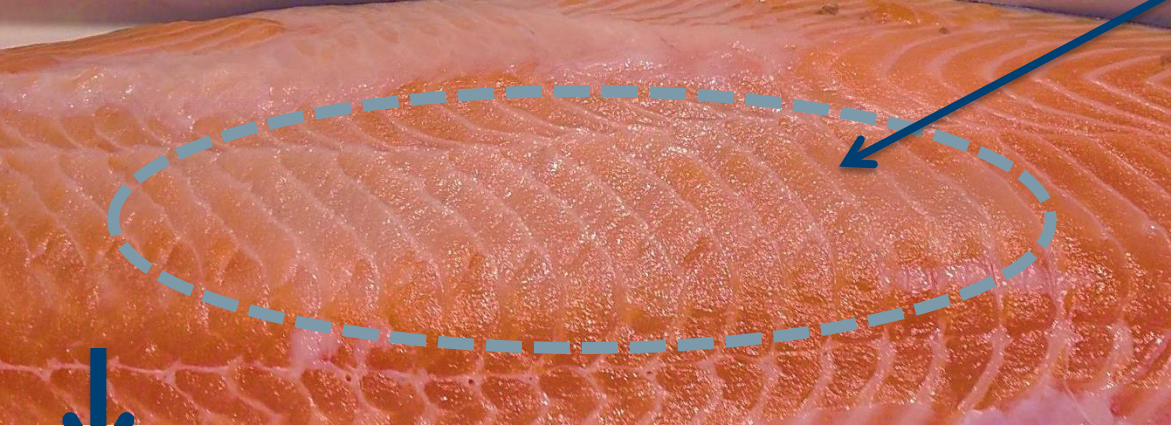
**"DARK SPOTS IN SALMON FILLETS"**  
 Workshop , BEST WESTERN Oslo  
 Airport Hotel  
 November 5<sup>th</sup> 2013

Melanin i laksefilet



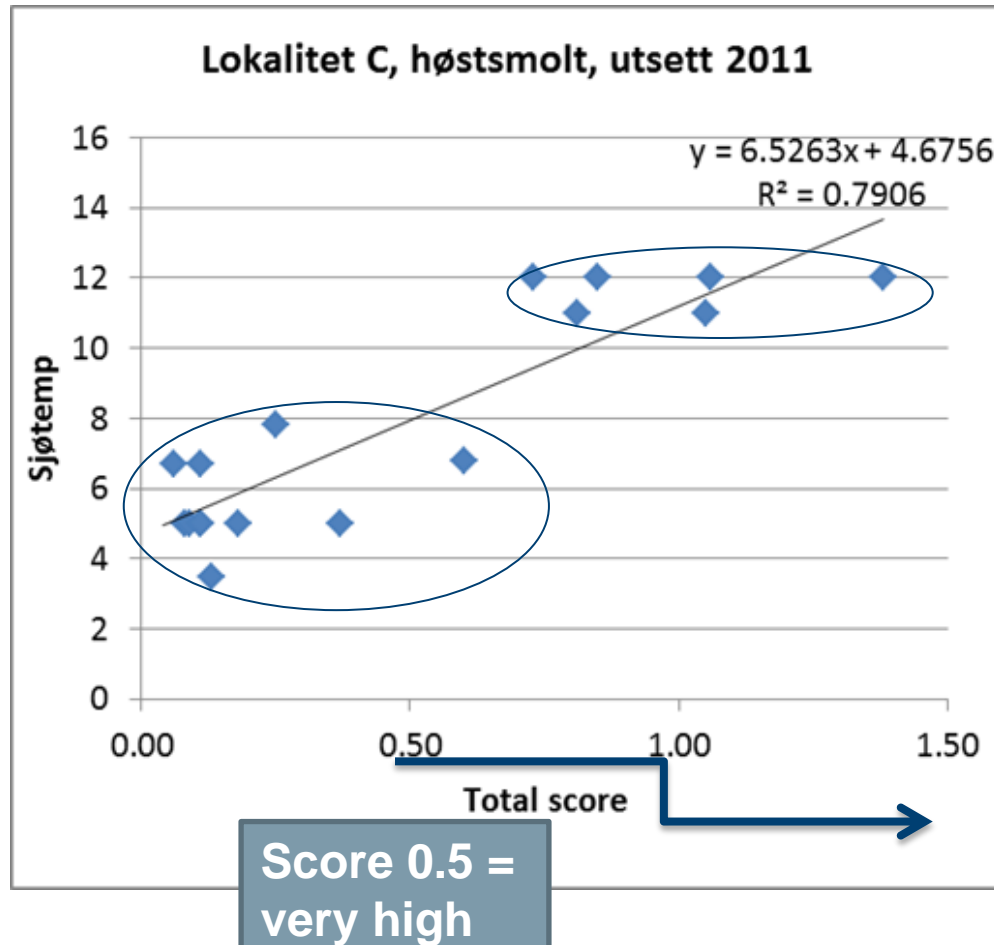
Inflammatory condition, dorsal muscle  
- no pathogens detected

Pale, gelly like



Increasing frequency coinciding with abrupt temperature rise  
Similar conditions seen after PD outbreak

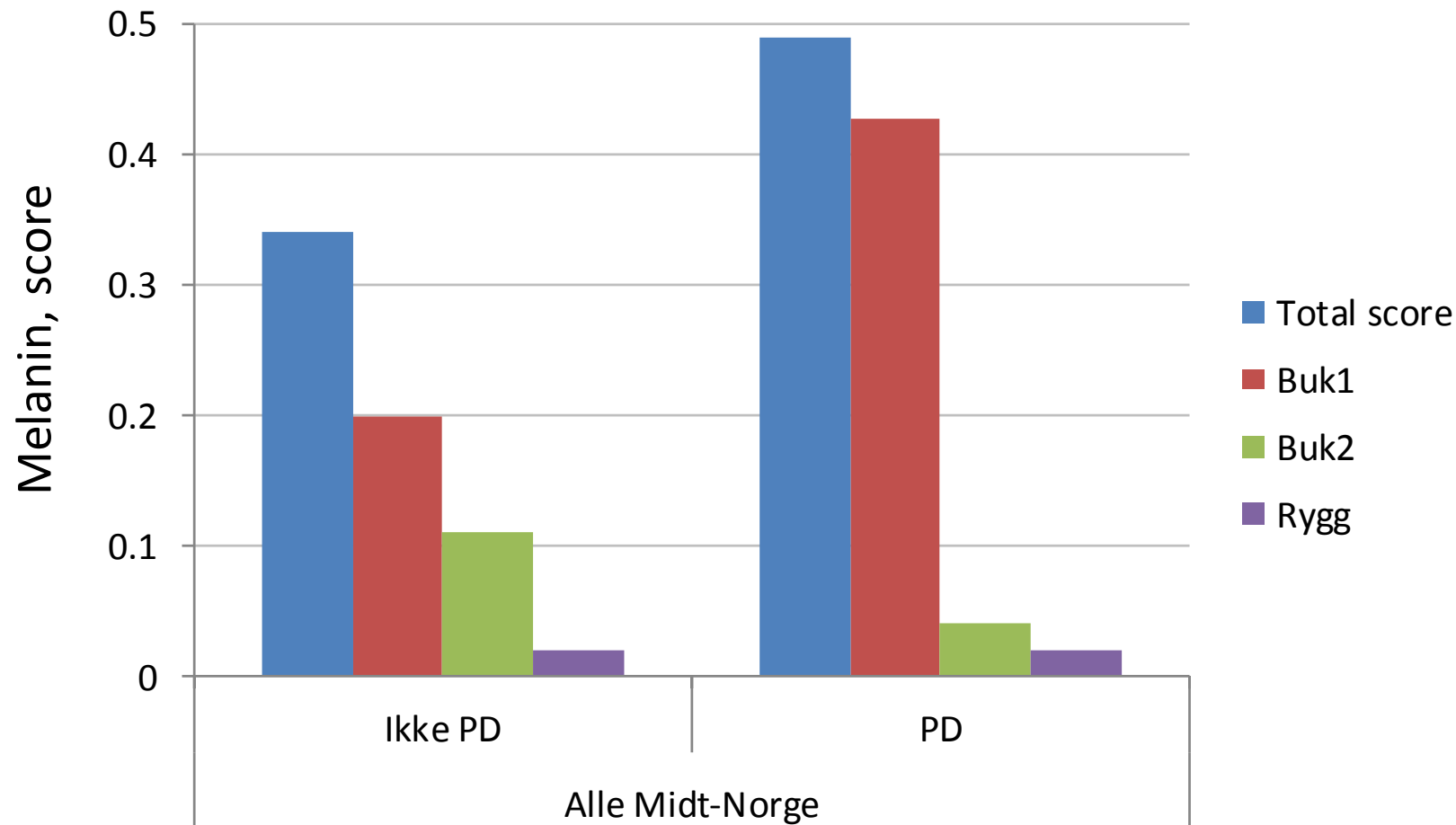
# Seawater temperature



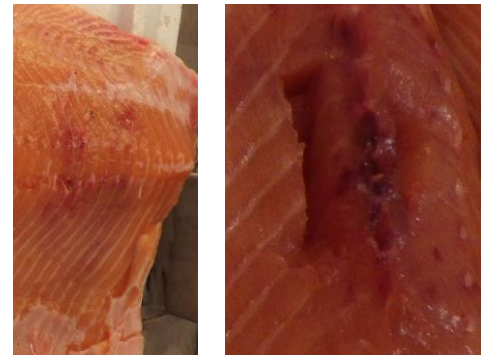Temperature induced stress?

# PD

## Other diseases?



- **The impact of health status / disease will be studied further**
- **VI has the responsibility of the diagnostics of selected farms in the project**



- Bleeding in the internal musculature after external physical traumatism, mimicing pumping, but only minor bleeding in the muscle under the skin. The depth of the haemorrhages varied
- Follow up on the impact of stress and mechanical injuries/ physical traumatism (focus on the impact of sorting fish)

# Stress

- **Mechanical:** sorting, injury
  - Does severe muscle contractions cause bleeding→pigment deposition
- **Disease:** stress may induce over-growth of «natural» bacteria.
  - Shown for e.g.aeromonas in carp, causing bleeding (hematoidin deposition)
  - Increased growth of such bacteria at higher temperatures
- **Environment:** oxygen level, temperature variations, salinity
- **Feed:** pro-oxidants etc may lead to increased level of haemociderin, lipofuscin,melanin
  - Macrophages from the head kidney may cause severe deposition when «cleaning up» affected areas
  - Feeding study: will be possible to study interaction between vaccine/feed/stress



# "Studies on stress and innate immunity in relation to infectious pancreatic necrosis virus in Atlantic salmon" 2012



Norges  
veterinærhøgskole

OPEN ACCESS Freely available online

PLOS ONE

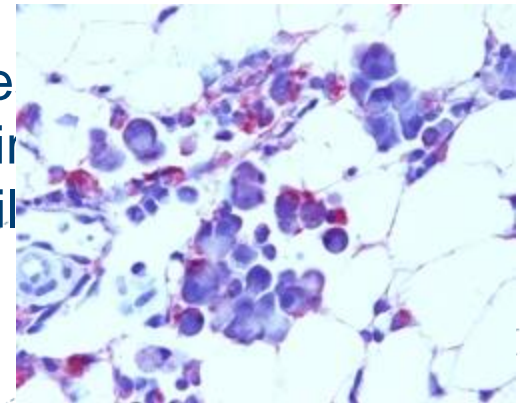
## Stress-Induced Reversion to Virulence of Infectious Pancreatic Necrosis Virus in Naïve Fry of Atlantic Salmon (*Salmo salar* L.)

Koestan Gadan<sup>1,2</sup>, Ane Sandtrø<sup>1,2</sup>, Inderjit S. Marjara<sup>1</sup>, Nina Santi<sup>2</sup>, Hetron M. Munang'andu<sup>1</sup>, Øystein Evensen<sup>1\*</sup>

<sup>1</sup>Norwegian School of Veterinary Science, Oslo, Norway, <sup>2</sup>Aqua Gen AS, Trondheim, Norway

yt kortisolnivå over  
ormering av virus  
gså vist at  
I resulterer i at

ellers ufarlige varianter av IPN-virus endres til sykdomsfremkallende virus. Med andre ord: stre immunforsvaret, øker «produksjonen» av IPN-vir indre organer og kan føre til «overgang» fra "snil varianter av virus.



Aeromonads, Mycobacteriosis +++  
.are other examples

"DARK SPOTS IN SALMON FILLETS"

Workshop , BEST WESTERN Oslo Airport Hotel

November 5<sup>th</sup> 2013

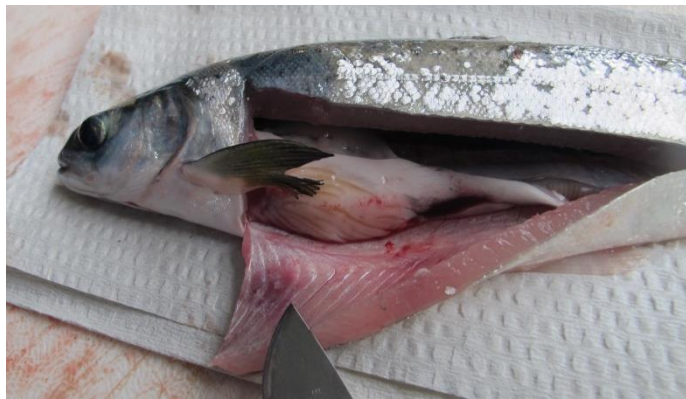 Nofima

# Dietary impacts

- Bleeding / coagulation
  - Nutritional imbalance
  - Fatty livers → the fish more vulnerable to stress?
  - Relevant minerals: Zn, Cu, Fe (coagulation factors)
  - Need more information on vascularisation
    - Why differences between the belly part and the tail



# Ungoing project



# 40 grams smolt before vaccination



## "DARK SPOTS IN SALMON FILLETS"

Workshop , BEST WESTERN Oslo Airport Hotel

November 5<sup>th</sup> 2013

# Summary

The problem is increasing

## Several causes to dark pigmentation of salmon fillets

- **Inflammation**
  - PD (SAV3 vs SAV2?)
  - Vaccine/ vaccination
  - Stress induced (e.g.temperature?)

- **Bleeding**

**Geographic variation**

**Severe variation between farms**

**Higher in 0+ than 1+ salmon**

**Not found systematic differences**

- Feeding companies
- Breeding companies
- Vaccine producers



# Relationship between melanin deposition in various tissues: organs, peritoneum, fillet

Jens Erik Dessen & Thomas Larsson, Nofima

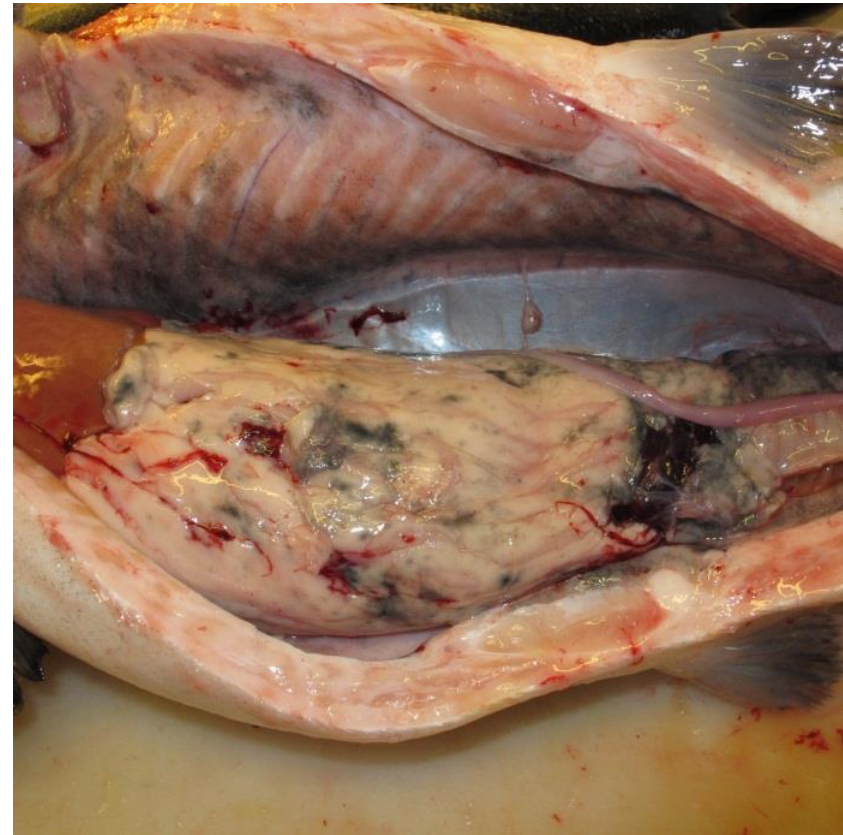
Workshop - Dark spots in salmon fillets

BEST WESTERN Oslo Airport Hotel, Gardermoen

November 5th 2013

# Melanin in organs, abdominal wall (peritoneum) and fillet

- Increase knowledge
- Possible implications for industry
  - Demanding markets
  - Sorting



# Quality classes

## - Superior


Produktet har følgende karakteristikker ved pakketidspunktet:

- a) glansfullt skinn uten betydelig skjelltap,
- b) ingen gjengrodde sår som reduserer helhetsinntrykket
- c) ingen åpne sår
- d) ingen bloduttredelser eller skader i buk eller muskulatur
- e) ingen melaninflekker i muskulatur
- f) hel, fast bukhinne
- g) hele eller avhelte (gjengrodde) finner
- h) naturlig strømlinjeformet fasong
- i) ingen vesentlige blødninger i skjellommene ved gattfinnen eller under bukhinnen

# National registration form

Melanin i filet (score)			
Ingen misfarging	0	Flekk 3 - 6cm	4
Grå skygge	1	Område større enn 6cm	8
Flekk mindre enn 3cm	2	Gjennomsnitt	0.24

registreringene sendes til [turid.morkore@nofima.no](mailto:turid.morkore@nofima.no)



% blek % gaping

BESVAR  
SPØRSMÅL⇒

Filet	Total score	Melanin i filet			Høyre=1	0	0
		Buk 1	Buk 2	Rygg	Venstre=2	Blek, 0-1	Gaping, 0-1
1	0	0	0	0			
2	0	0	0	0			
3	1	1	0	0			
4	0	0	0	0			
5	1	1	0	0			
6	1	1	0	0			
7	0	0	0	0			
8	0	0	0	0			
9	0	0	0	0			
10	0	0	0	0			
11	0	0	0	0			
12	0	0	0	0			
13	0	0	0	0			
14	0	0	0	0			
15	0	0	0	0			
16	0	0	0	0			
17	0	0	0	0			
18	0	0	0	0			
19	0	0	0	0			
20	0	0	0	0			
21	0	0	0	0			
22	0	0	0	0			
23	1	1	0	0			
24	1	1	0	0			
25	0	0	0	0			
26	0	0	0	0			
27	0	0	0	0			

## SPØRSMÅL SOM BESVARES FOR HVER GRUPPE FISK SOM BEDØMMES

Navn på prosessanlegg			
Navn på bedømmer			
Lokalitetsnavn (nr)			
Dato ved slakt	07.10.2011	Sjøtemp	
Dato ved måling/klokke	11.10.11 15.40	Superior	Ordinær
Vektklasse	4-5.	Merd nr	Lot nr.

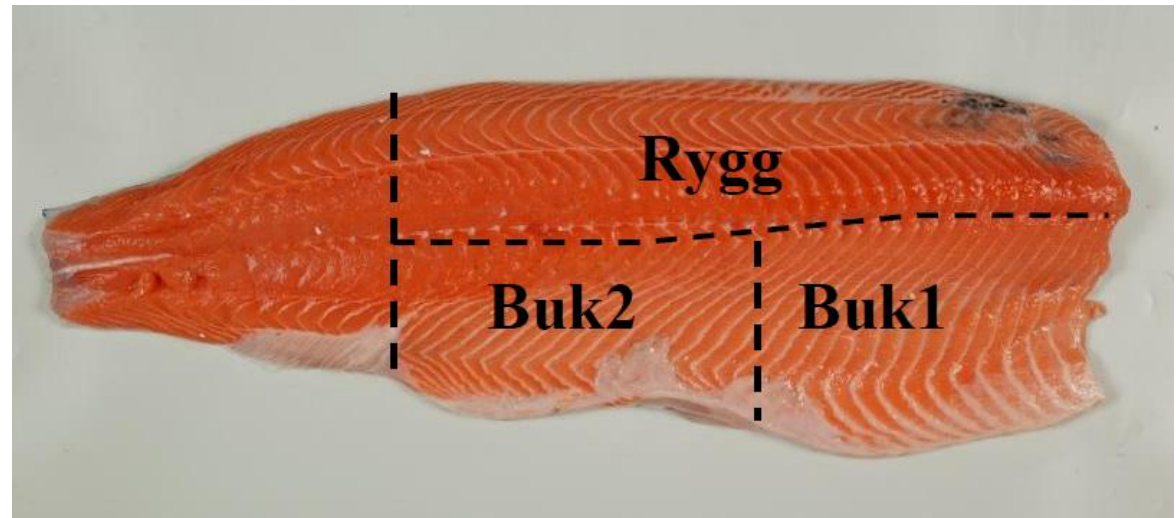
## TILLEGGSINFORMASJON

<b>Smolt</b>	
Leverandør:	
Utsett, mnd/år:	Stamme:
Maskinvaksinert	NEI JA
Vaksintype:	

<b>Slaktefisk</b>			
Sultetid, dager:	NEI JA	Fôrtype før slakt*:	NEI DAGER
Brønnbåt	<input type="checkbox"/> <input checked="" type="checkbox"/>	Ventemerd	<input type="checkbox"/> <input type="checkbox"/> 1
Awik for partiet	NEI JA	Brusk/deform	NEI JA
Bløt filet	<input type="checkbox"/> <input type="checkbox"/>	Annet:	
Aviving	Slag CO <sub>2</sub>	Strøm	Annet
	<input type="checkbox"/> <input type="checkbox"/>	<input checked="" type="checkbox"/> <input type="checkbox"/>	
	Vet ikke Nei Ja		Navn/tidspkt/dødelighet <sup>2</sup>

# National registration form

## Filet areas



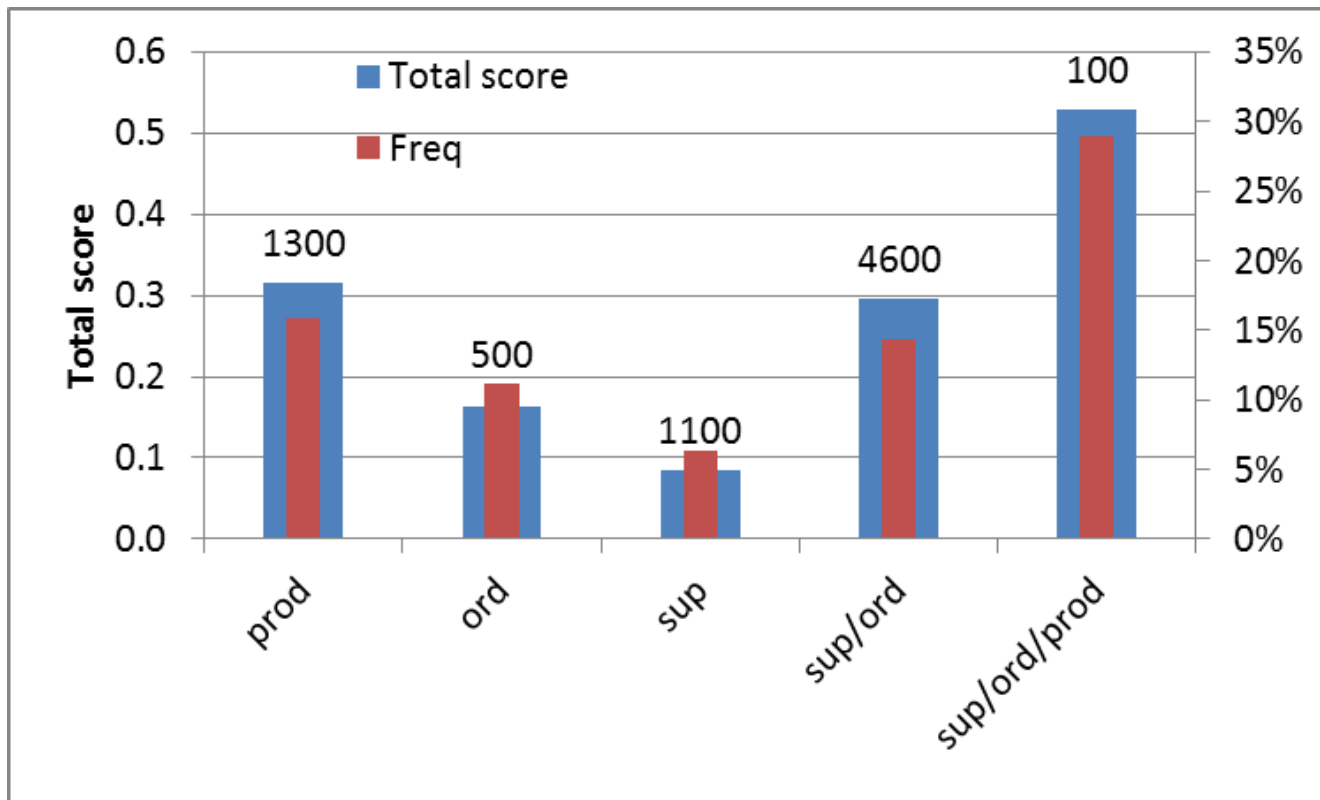
## Scale

Melanin i filet (score)			
Ingen misfarging	0	Flekk 3 - 6cm	4
Grå skygge	1	Område større enn 6cm	8
Flekk mindre enn 3cm	2		



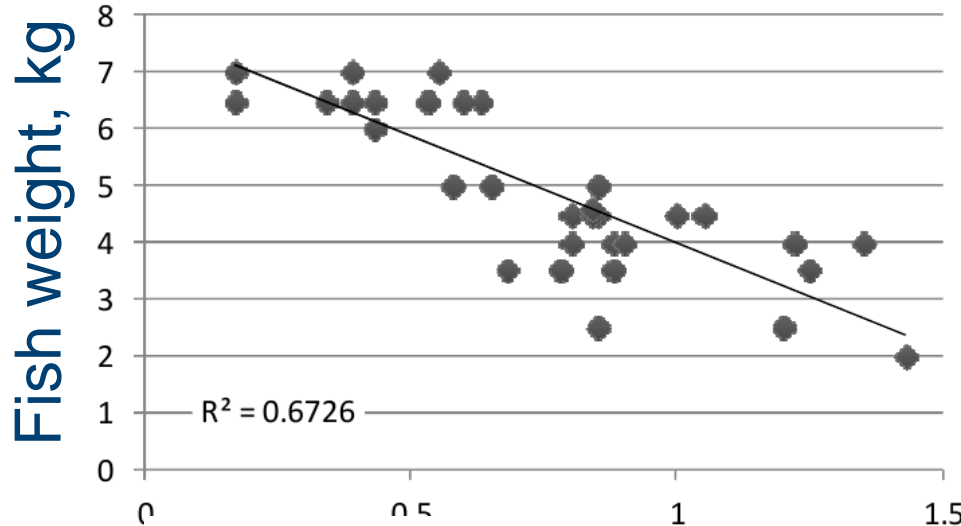
# Quality classes – dark spots in fillet

- Tendency of higher frequency of dark spots in fillets of Production fish
- No clear differences between Superior / Ordinary

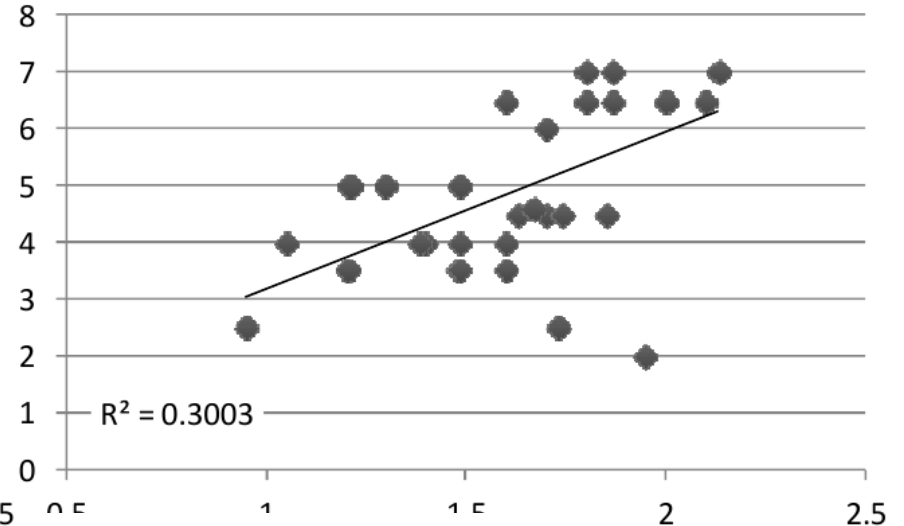


# Organs and abdominal wall

Melanin i organer og størrelse



Melanin i bukvegg og størrelse



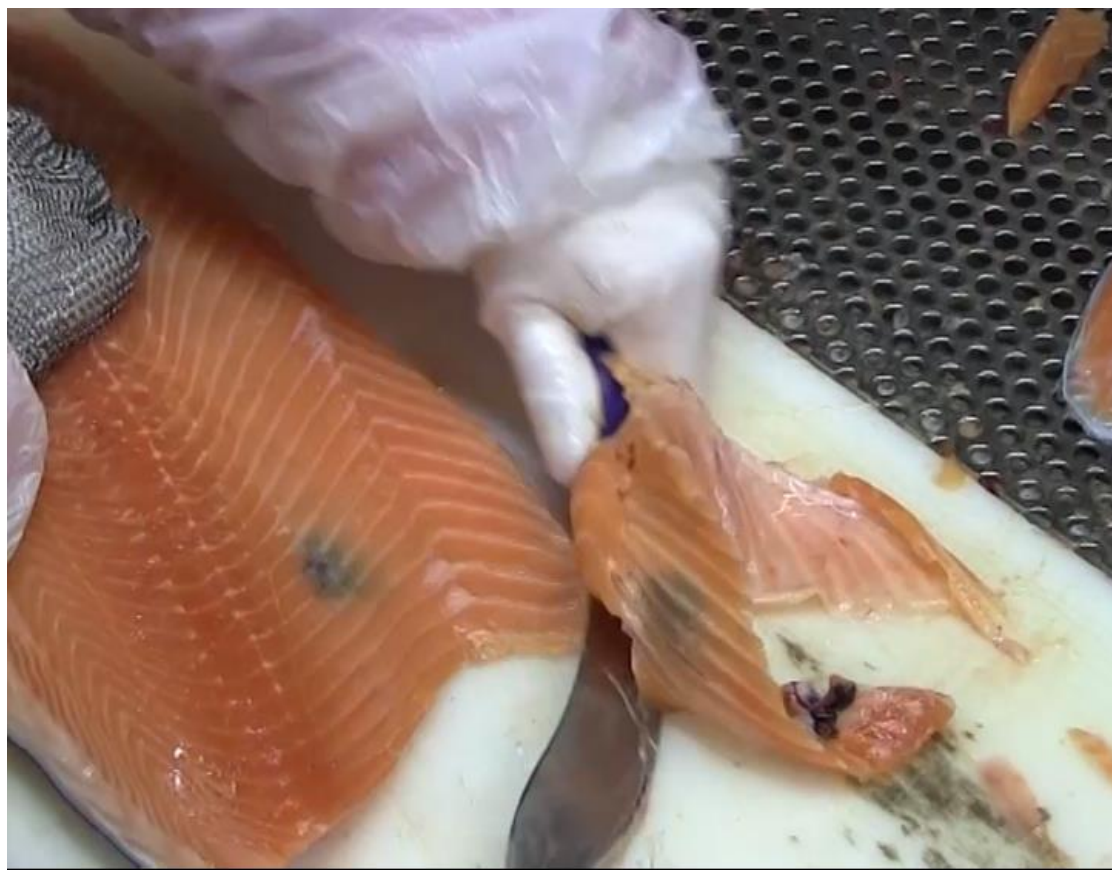Melanin in organs, score (0-3)

Melanin in abd.wall score (0-3)

- On individual basis (n = 915), the correlation between melanin in organs and abdominal wall = 0.24

# Relationship between dark spots in abdominal wall and fillet

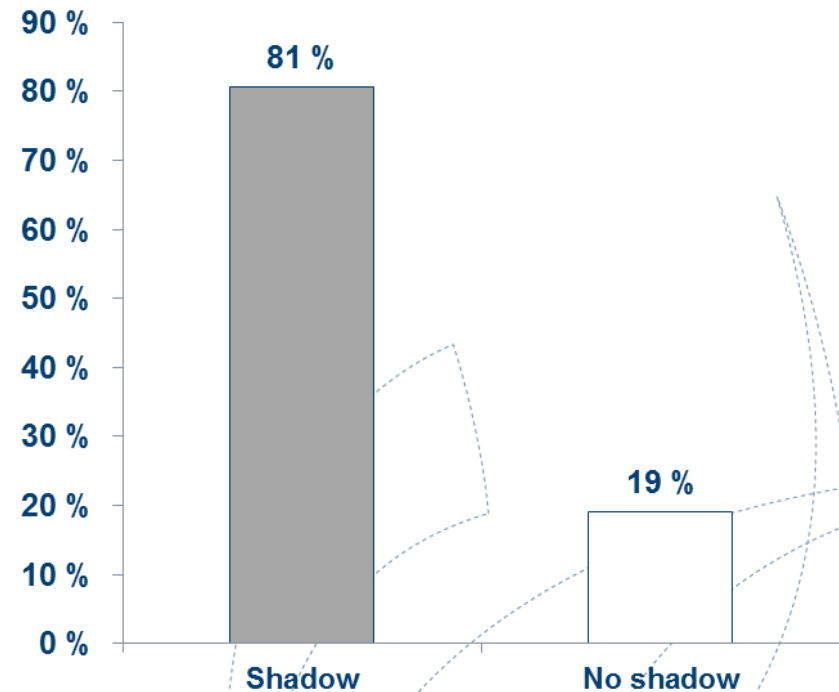
## - preliminary results



# Relationship between dark spots in abdominal wall and fillet

## - Test 1

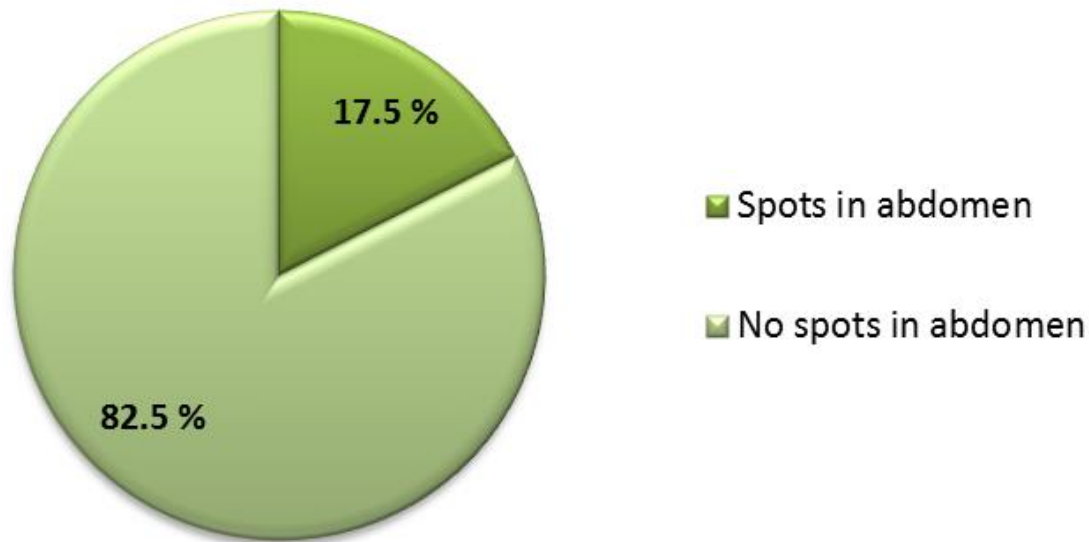
- Class: Superior (3.7 – 5 kg)
- 400 fish, visually evaluated before and after trimming
- «Shadow» in the abdominal wall and clear spots in the abdominal wall and fillet were recorded



# Relationship between dark spots in abdominal wall and fillet

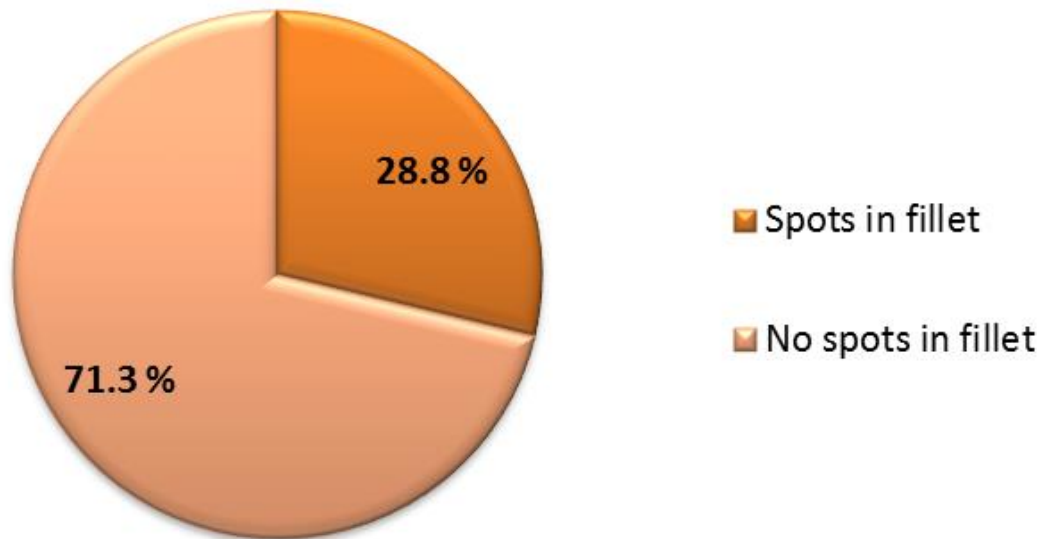
## - Test 1

**% fish with melanin spots in abdominal wall**



# Relationship between dark spots in abdominal wall and fillet - Test 1

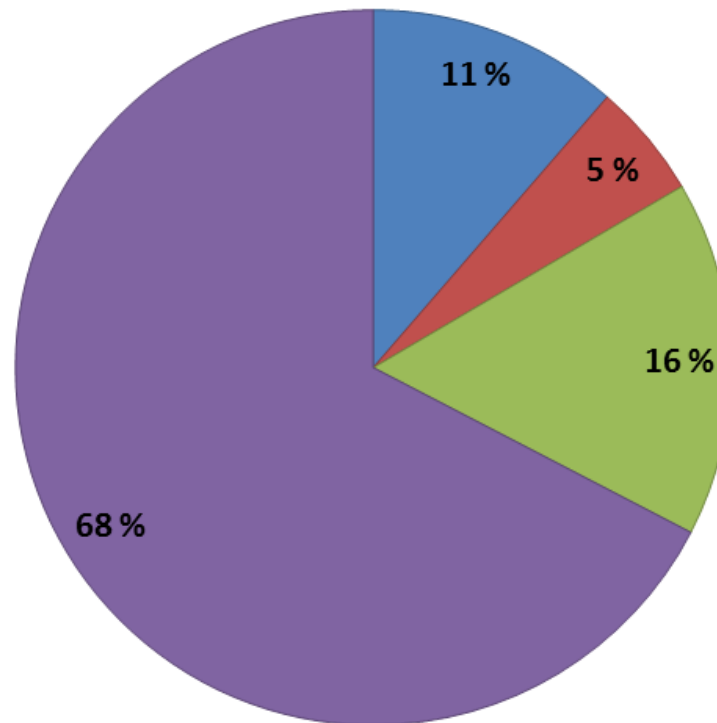
## % fish with melanin spots in fillet



# Relationship between dark spots in abdominal wall and fillet - Test 1

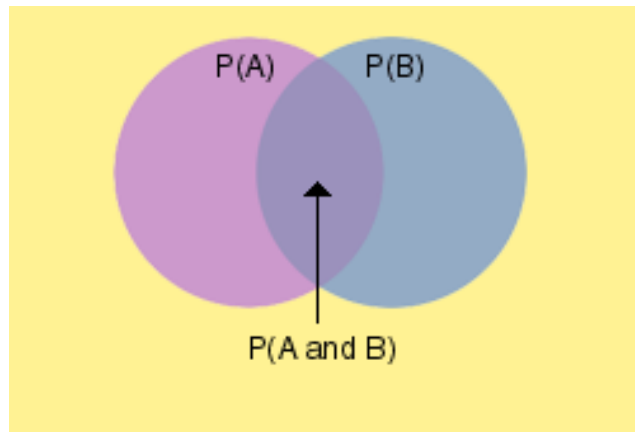
## Distribution of spots in abdominal wall and fillet

■ Spots in abdomen and fillet   ■ Spots only in abdomen   ■ Spots only in fillet   ■ No spots



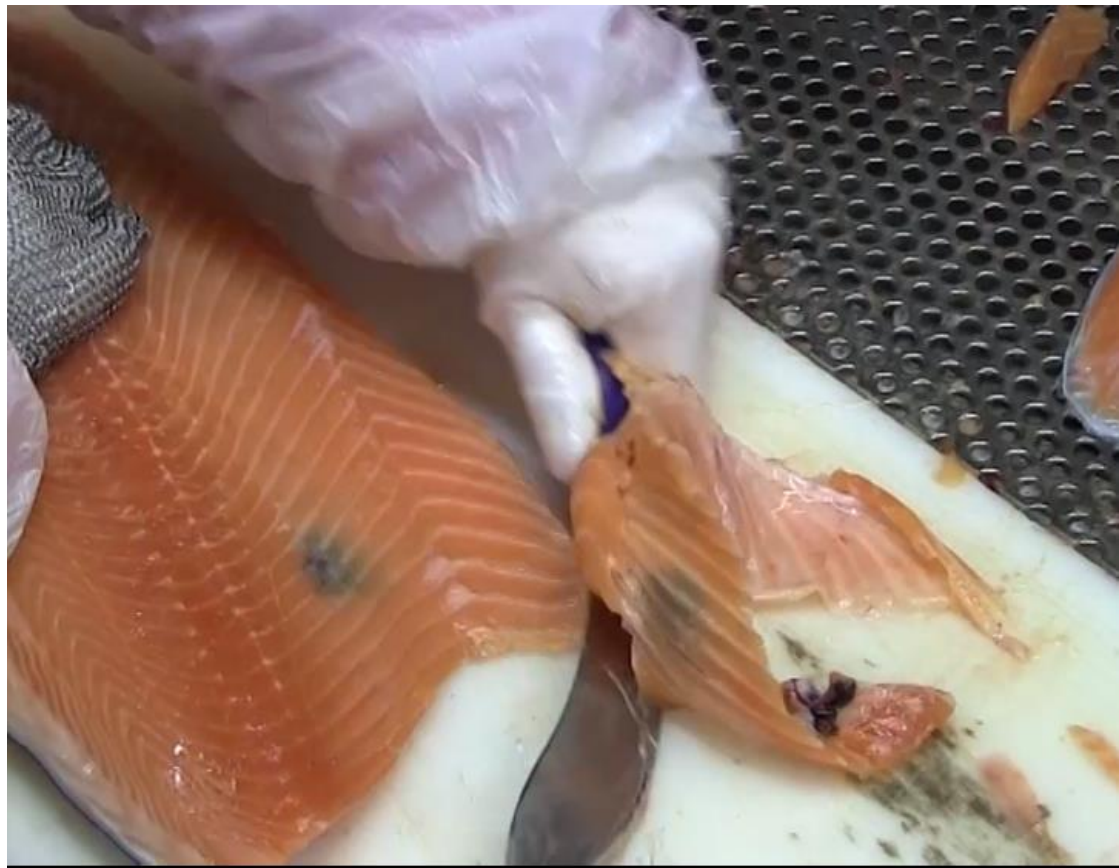# Probability – test 1

- Probability of having a spot in the fillet when there is a spot detected in the abdominal wall = 0.69
- Probability of having a spot in the abdominal wall when there is a spot in the fillet = 0.41







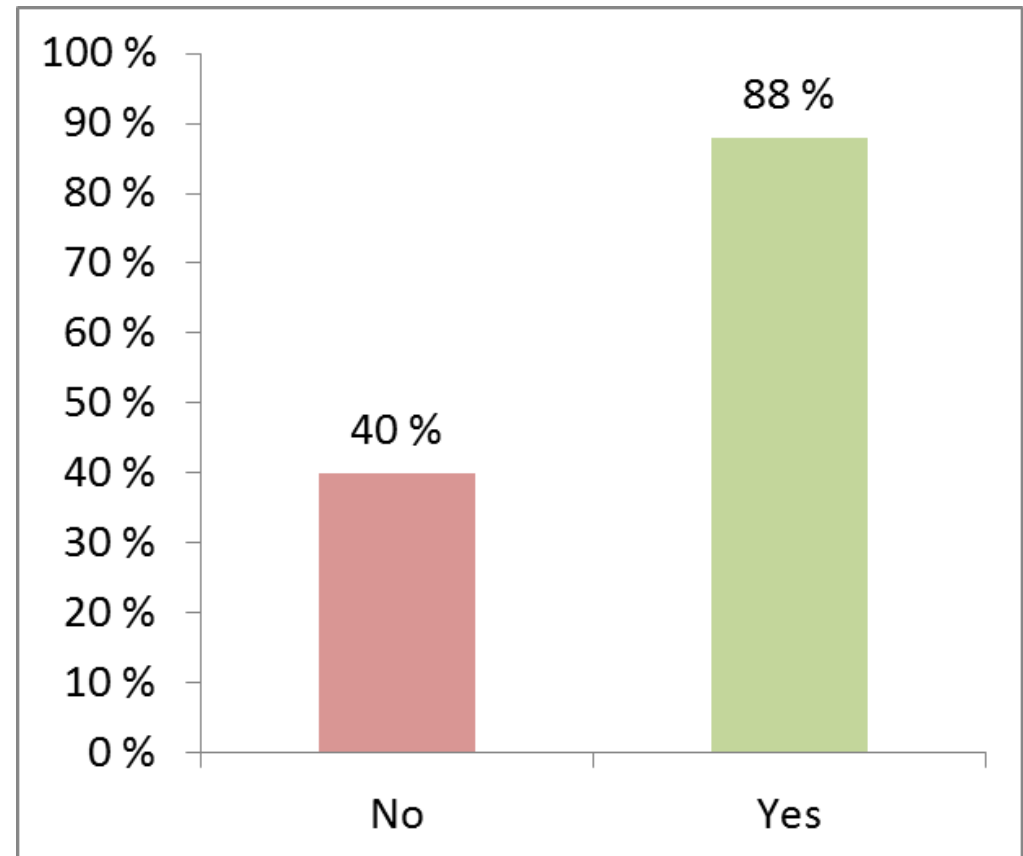




# Relationship between dark spots in abdominal wall and fillet

## - Test 2

- Class: Superior/Ordinary (4-5 kg)
- 50 fish with (= YES) and 50 without (= NO) spots in the abdominal wall
- Visually evaluated before and after trimming
- Highly significant difference



# Preliminary conclusions

- No clear relationship between melanin in organs and abdominal wall
  - But appear to have different causes
- Higher frequency of dark spots (and perhaps also larger spots) in muscle than in abdominal wall
- Sorting based on dark spots in abdominal wall may be important for high quality products

A photograph of a brown trout lying on a bed of moss and small green plants. The trout is positioned horizontally, facing right, with its mouth wide open, showing its pinkish-red interior. The fish has a mottled pattern of dark spots on its back and sides, and a lighter, silvery-white belly. The background is a dense carpet of moss and small green plants, with some dry, brownish grass blades scattered throughout. The text "Thank you!!" is overlaid in a dark blue, sans-serif font across the middle of the fish's body.

Thank you!!